

## Penetrating brain injury: a case report

Katarzyna Śmiłowska<sup>1</sup>, Justyna Pytel<sup>2</sup>, Lech Krawczyk<sup>1</sup>, Marek Śmiłowski<sup>3</sup>, Przemysław Jałowiecki<sup>1</sup>

<sup>1</sup>*Department of Anaesthesiology, Intensive Care and Emergency Medicine in Zabrze, Medical University of Silesia in Katowice, Poland*

<sup>2</sup>*Student Scientific Society, Department of Anaesthesiology, Intensive Care and Emergency Medicine in Zabrze, Medical University of Silesia in Katowice, Poland*

<sup>3</sup>*Department of Neurology, Medical University of Silesia in Katowice, Poland*

### Abstract

**Background:** Gunshot wounds as a result of attempted suicide, criminality or warfare comprise a significant group among penetrating injuries of the brain. A prognosis in such cases is based mainly on an initial score on the Glasgow Coma Scale (GCS). According to the literature, the mortality rate among patients with initial GCS ranging from 3 to 5 points is very high, up to 98.5%. Although there are also many other prognostic factors for high mortality, such as damage to the ventricular system or the involvement of two or more lobes, GCS score seems to be the most important determinant. The treatment in an ICU which is focused on decreasing the risk of secondary brain damage can significantly improve the prognosis and final outcome.

**Case report:** The authors present the case of a 27-year-old man who suffered a gunshot wound to the right temporal region, self-inflicted from an air-gun. On admission to the intensive care unit he received a score of 3 points on the GCS. There were also other negative prognostic factors — the pellet penetrated two lobes and damaged the third ventricle. Despite the serious prognosis, the appropriate multiprofile treatment and rehabilitation resulted in unexpectedly good recovery. Two years after the trauma the patient was conscious, maintained logical verbal contact, and was able to walk using a walking-aid.

**Conclusion:** Rapid transport to a major trauma center is essential for patients with penetrating brain injury. Among all interventions it seems essential to provide the prevention of posttraumatic nervous tissue damage and associated neurological dysfunction.

**Key words:** critical care, trauma; trauma, brain; wounds, gunshot; wounds, penetrating

Anestezjologia Intensywna Terapia 2015, tom XLVII, nr 3, 221–225

Penetrating brain injury (PBI) is defined as an injury with tearing of the dura mater, the outer layer of the meninges. The majority of penetrating brain injuries are the result of attempted suicides, assaults and accidents. Penetrating craniocerebral gunshot wounds are very often lethal injuries, despite all medical and surgical interventions [1–3]. The prognosis in such cases is based mainly on an initial score on the Glasgow Coma Scale (GCS).

### CASE PRESENTATION

A 27-year-old man was admitted to the hospital with a brain injury as a result of air-gunshot suicide attempt. The entrance wound was located in the right temporal region. Six of seven pellets enclosed in the fired shell remained in the skin, subcutaneous tissues and temporal bone. One pellet penetrated the left occipital lobe, crossing the medial line of the brain. There was no evi-

Należy cytować wersję:

Śmiłowska K, Pytel J, Krawczyk L, Śmiłowski M, Jałowiecki P: Penetrating brain injury: a case report. *Anaesthesiol Intensive Ther* 2015; 47: 214–218.

dence of an exit wound: the pellet remained in the left occipital lobe. An X-ray of the head showed the position of all pellets (Figs 1, 2). On admission to the ICU in the local hospital the patient was unconscious with a GCS of 3 points and mechanically ventilated. Initial treatment at the local hospital included fluids, analgesics, antibiotics, diuretics, mannitol, cyclonamine, vitamin K and ranitidine. Thiopentone was used to put the patient into a barbiturate-induced coma.

A CT scan of the head performed on the day of the trauma revealed generalized cerebral edema, a large amount of blood in the subarachnoid space, fourth ventricle and supratentorial ventricular system. Bilateral pneumocranium was observed. A few metallic foreign bodies were visualized in the right temporal region and one in the left parietal lobe. The trajectory of the projectile led bilaterally through the thalamus and the third ventricle, extending from the right temporal region to the left parietal region (Fig. 3).

On the 3<sup>rd</sup> day following the injury, the patient was transferred from a local hospital to the Medical University Trauma Center, where he was hospitalized for six weeks. On admission the patient was still unconscious, sedated with thiopentone and fentanyl. His pupils were small, of equal size, with poor response to light. There was no response to pain stimuli. Instead of the unclear sentence should be: In the ICU routine monitoring (pulse oximetry, end-tidal CO<sub>2</sub>, arterial and central venous blood pressures, electrocardiography, body temperature and fluid balance) was initiated.

Different ventilation modes including continuous mandatory ventilation and synchronized intermittent mandatory ventilation, as well as positive end-expiratory pressure with an average of 6 cm H<sub>2</sub>O were administered to maintain PaO<sub>2</sub> ≥ 80 mm Hg and PaCO<sub>2</sub> ≥ 32 mm Hg.

The incidence of ventilator-associated pneumonia (VAP) caused by: *Pseudomonas aeruginosa*, *Klebsiella pneumoniae*, *Enterobacter cloacae*, *Acinetobacter baumannii* and *Staphylococcus aureus* was treated in accordance with the antibiogram including amoxicillin, cephalosporins, imipenem-cilastatin, metronidazole, and clarithromycin. Multiple therapeutic bronchoscopies were necessary due to recurring bilateral atelectasis. A tracheostomy was performed on the 14<sup>th</sup> day of hospitalization. After 4 weeks the patient's condition improved — consequently, the ventilator was disconnected. Decannulation was possible on the 41<sup>st</sup> day following injury.

At the beginning of the hospitalization period the patient required administration of norepinephrine (2–4 µg min<sup>-1</sup>) and dopamine (2 µg kg<sup>-1</sup> min<sup>-1</sup>) to maintain a mean ar-

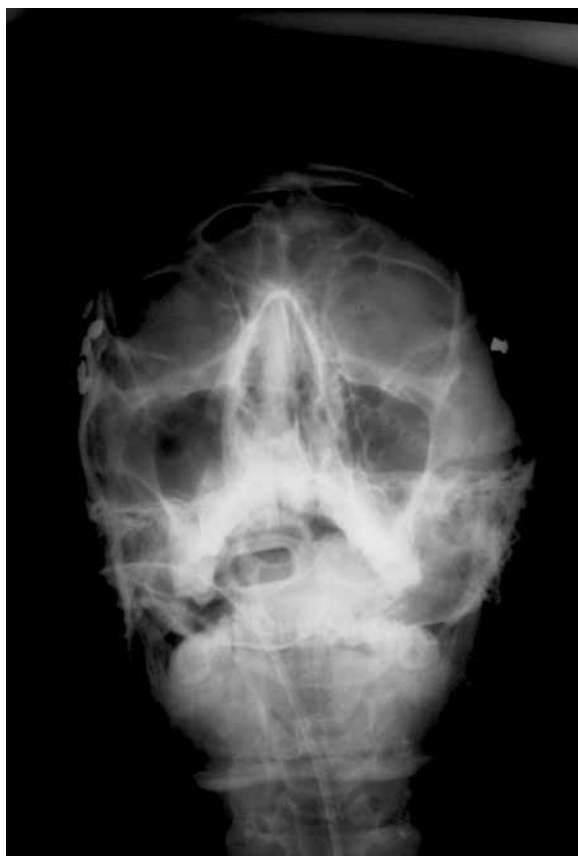

Figure 1. Head X-ray showing pellets in the skull

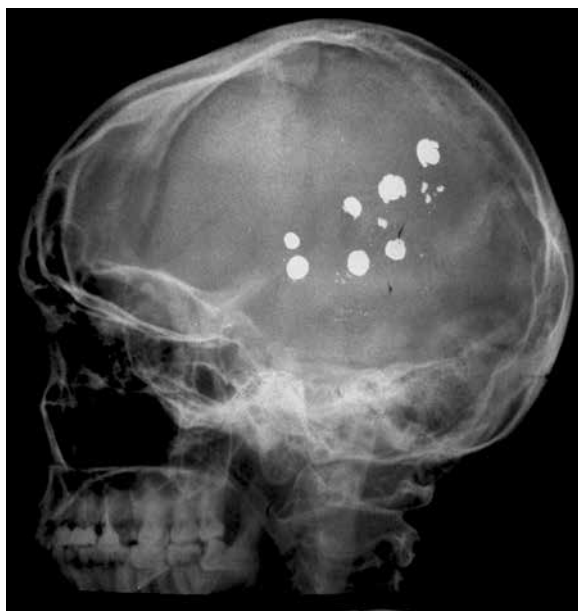
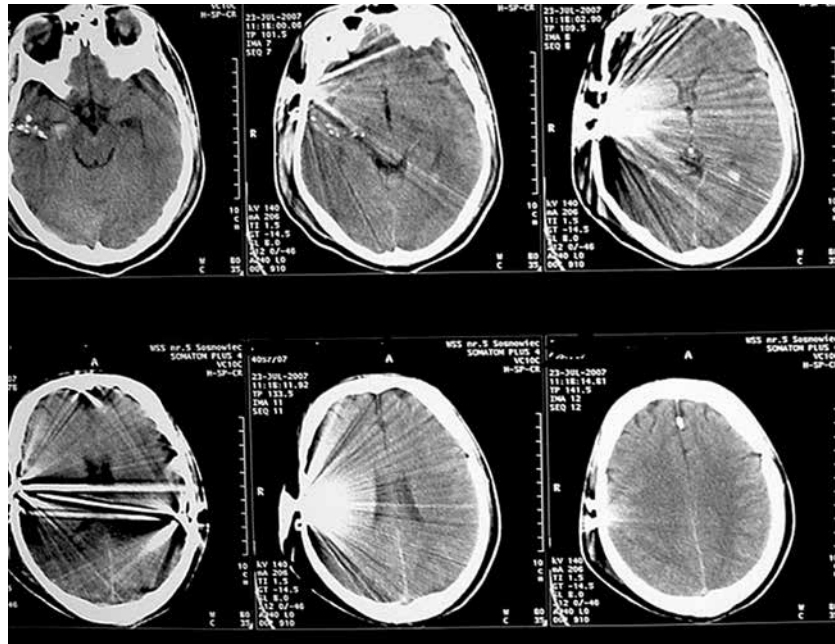


Figure 2. Head X-ray performed at the day of the trauma



**Figure 3.** Head — CT scan performed at the day of the trauma

terial pressure of 80 mm Hg. In order to reduce the risk of secondary brain injury, continuous infusion of thiopentone at 4–8 mg kg<sup>-1</sup> h<sup>-1</sup> was necessary for the first 2 weeks of treatment. Mannitol was administered for the first 12 days at a daily dose of 250 g. Cloxacillin and clindamycin were administered to prevent meningoencephalitis. Enteral feeding agents, analgesics, diuretics, proton pump inhibitors were also administered in accordance with the patient's clinical status.

Slight motor response to pain stimuli in right shoulder was observed from the 7<sup>th</sup> day of treatment. Subsequently, from the 16<sup>th</sup> day, a continuous improvement in the patient's general condition was noted. He regained consciousness and followed simple commands appropriately. Left side paralysis and severe right-sided paresis gradually improved over the next several months of rehabilitation.

Over six weeks in the ICU, follow-up CT head scans were performed three times showing a gradual regression of observed abnormalities.

According to a neurosurgical examination, there were no indications for urgent surgical intervention in the first weeks of hospitalization. However, after about one month of the treatment involuntary movements of the head and right arm were observed. An EEG examination performed at that time showed focal abnormalities in the left occipital region and seizure activity in both occipital regions. The findings were consistent with the abnormalities observed on CT scans. Due to a poor response to anticonvulsants, a stereotactic craniotomy was performed three months after

the trauma with the removal of the pellet remaining in the left occipital lobe. The procedure resulted in a significant decrease in the involuntary movements.

A year after the trauma the involuntary movements, although less intensive than initially, were still present. Asymmetric spastic tetraparesis (left > right) with the bilateral Babinski sign and ankle clonus on the left side were observed. The functional state was evaluated by means of the Barthel scale. Although, initially, the patient scored 30 points, after few weeks of rehabilitation his condition improved significantly and he scored 55 points.

Two years after the trauma, a follow-up neurological examination showed that the patient was alert and conscious, maintained logical verbal contact. However, left side temporal hemianopsia, a lack of left pupil response to light, a lack of convergent movement of the right eyeball, and central facial palsy on the left side were detected together with spastic dysarthria and an impaired swallowing reflex. Pyramidal tetraparesis was still present, with bilaterally exaggerated deep tendon reflex, predominantly on the left side. Involuntary movements of the head and right upper limb were also observed during examination.

## DISCUSSION

According to the literature, the majority of PBI results from attempted suicides, assaults and accidents. There are few reports available in the literature that describe air-gun inflicted wounds which makes it difficult to perform comparative studies. Moreover, the extent of brain damage

caused by a gunshot is different in each case, depending on the material the bullet is composed of. Air-gun head injuries are more common in children as a result of an accidental gunshot. Martínez-Lage et al. [4] presented three cases of injury from an air-gun in children. One of them concerned an 18-month-old girl whose CT scan revealed a pellet in right parietal lobe. On admission to the hospital the child was drowsy but without focal neurologic deficit. The patient received prophylactic antibiotics, antiepileptic treatment and was discharged home. After a 5-year follow-up, the child was asymptomatic. The second patient was a 13-year-old boy, who shot himself in the right temple. As no breach of the dura was observed, the case does not meet PBI criteria. The most similar case reports are provided by Dalgic et al. [5], who presented two cases of air-gun victims: first, a 15-year-old male suffering a gunshot wound to the temporal region. On admission, he had a GCS score of 12 points and no focal symptoms were observed. The second case was a 40-year-old man with an injury to the parietooccipital region without focal neurological symptoms. In both cases duraplasty was performed and cerebral anti-edema treatment, anti-epileptics and prophylactic antibiotics were administered.

In the above-cited cases, the GCS score at admission was significantly higher (the lowest GCS score was 12 points) than in our patient. Moreover, the pellets did not cross the midline, and no damage of the cerebral ventricles was observed. Such differences in nervous tissue damage may result from an increased velocity of the pellets which depends on their weight and shape. The damaging effect of air-gun injuries might be therefore increased with user modification, as in the case reported [5].

Martins et al. [6] divided 319 patients with gunshot wounds into 4 groups according to their GCS score. In the group with a GCS score ranging from 4 to 5 points, consisting of 125 patients, the mortality rate reached 98.5%. Only 2 of these patients were discharged from the ICU, both in a persistent vegetative state. Clark et al. [7] examined 76 patients, including 33 with a GCS ranging from 3 to 4 points, and none of them survived. Aldrich et al. [8] presented a series of 151 patients who suffered gunshot wounds whose overall mortality was 88%. Among those with an initial GCS score of 3–5, the authors noted a mortality rate of 94%, whereas among patients with a GCS score of 6–8, the mortality rate was 70%. Moreover, it was pointed out that there were no good outcomes at all and only three moderate recoveries in a group of patients with initial scores of 8 or less. Hernesniemi reported, that a mortality rate of only 22% was observed in patients who were conscious on admission, and 93% if the patients were unconscious [9]. Graham et al. [10] described a group of patients with a GCS score of 3–5: none of them had a satisfactory outcome despite aggressive treatment

procedures. The authors studied 100 consecutive patients prospectively to establish a systematic approach to treatment. The outcome progressively improved with an increasing GCS score. They concluded that if the patient's GCS score ranges from 3 to 5 and no operable hematomas are present, no further surgical treatment should be offered. However, all patients with a GCS score greater than 5 should receive aggressive surgical treatment [10]. These observations are consistent with our case, where no urgent surgical intervention was performed and the pharmacological treatment had an unexpectedly satisfactory outcome.

Most authors agree that the main prognostic factor in penetrating brain injury is the GCS score on admission. It is estimated that the survival rate from gunshot wounds to the head ranges from 3% for a GCS of 3–5, up to 52% for a GCS of 6–8, and 92% for a GCS of 9–12. Moreover, among those patients with GCS score of 13–15 the survival rate reaches 100% [6]. Among other negative predictors, apart from a low GCS score, authors mention ventricular damage, bihemispheric wound, unilateral dilated or medium fixed pupil [1].

Hashimoto et al. [11] divided traumatic intraventricular hemorrhage into four types as follows: type 1 — massive hemorrhage; type 2 — subependymal hemorrhage; type 3 — damage of the fornix or septum pellucidum; and type 4 — Nieuveau (fluid-blood level). Blood in the ventricle obstructs the cerebro-spinal fluid drainage system and leads to ventricular enlargement and hydrocephalus which is a life-threatening situation requiring rapid neurosurgical intervention.

According to the literature, the management of penetrating brain injury should follow valid evidence-based protocols. The current 3<sup>rd</sup> edition of "Guidance for the management of severe traumatic brain injury", published by the Brain Trauma Foundation, pointed out the value of appropriate monitoring (general and neuromonitoring) which is crucial for the early detection of secondary brain injury [12, 13]. General monitoring includes arterial oxygen saturation, arterial blood pressure, electrocardiography, capnography, central venous pressure, temperature measurement, fluid balance and urine volume. Neuromonitoring covers parameters such as intracranial pressure monitoring (ICP), jugular bulb venous oxygen saturation ( $S_{jvO_2}$ ), brain tissue oxygen tension ( $P_{btO_2}$ ), cerebral microdialysis (MD), electroencephalography (EEG) and transcranial Doppler (TCD).

There have been no randomized trials supporting the thesis that ICP monitoring impacts the final PBI outcome. Nevertheless, this parameter should be monitored in "all salvageable patients with severe traumatic brain injury and abnormal computed tomography (CT) scan" [14, 15].

To reduce cerebral perfusion, hyperventilation should be avoided. The only exception to this recommendation is the case of severe neurological exacerbation, but only for

a short period (20 min on average) and after 24 h of brain trauma occurrence. It is worth mentioning that prolonged hyperventilation causes ischemia due to vasoconstriction. Patients with penetrating brain injury usually are mechanically ventilated. The aim of hyperventilation is to achieve normal ventilation defined as a pulse oximetry ( $\text{SpO}_2 > 95\%$ ,  $\text{PaO}_2$  of 80 mm Hg and  $\text{PaCO}_2$  of 35 to 40 mm Hg). It is recommended to support ventilation with PEEP (5–8 cm  $\text{H}_2\text{O}$ ) to preserve optimal oxygenation.

Isotonic crystalloids should be administered as a first line therapy to maintain proper intravascular volume. In similar cases mannitol should be used at a dose of 1 g  $\text{kg}^{-1}$ . Higher doses are required in acute intracranial hematoma mainly prior to surgery. Due to increased risk of death, steroids should be avoided in brain trauma patients [14].

Based on the authors' observation, rapid transport to a major trauma center is essential for patients with penetrating brain injury. This is the only place where complex care can be provided. Among all interventions, this seems essential in order to provide the prevention of posttraumatic nervous tissue damage and associated neurological dysfunction.

In this particular case, due to proper neuroprotection, we managed to avoid secondary axonal degeneration and dementia, the most common posttraumatic complication.

## ACKNOWLEDGEMENTS

1. The authors declare no financial disclosure.
2. The authors declare no conflict of interest.

## References:

1. *Erdogan E, Izci Y, Gonul E, Timurkaynak E*: Ventricular injury following cranial gunshot wounds: clinical study. *Mil Med* 2004; 169: 691–695.
2. *Rosenfeld J*: Gunshot injury to the head and spine. *J Clin Neurosci* 2002; 9: 9–16.

3. *Kriet J, Stanley R, Grady M*: Self-inflicted submental and transoral gunshot wounds that produce nonfatal brain injuries: management and prognosis. *J Neurosurg* 2005; 102: 1029–1032.
4. *Martínez-Lage J, Mesones J, Gilabert A*: Air-gun pellet injuries to the head and neck in children. *Pediatr Surg Int* 2001; 17: 657–660.
5. *Dalgic A, Okay O, Ergunor F, Uckun O, Nacar O, Yildirim A*: Brain injury due to air gun shot: report of three adult cases. *Ulus Travma Acil Cerrahi Derg* 2010; 16: 473–476.
6. *Martins R, Siqueira M, Santos M, Zanon-Collange N, Moraes O*: Prognostic factors and treatment of penetrating gunshot wounds to the head. *Surg Neurol* 2003; 60: 98–104.
7. *Clark W, Muhlbauer M, Watridge C, Ray M*: Analysis of 76 civilian cranio-cerebral gunshot wounds. *J Neurosurg* 1986; 65: 9–14.
8. *Aldrich EF, Eisenberg H, Saydjari C et al.*: Predictors of mortality in severely head-injured patients with civilian gunshot wounds: a report from the NIH Traumatic Coma Data Bank. *Surg Neurol* 1992; 38: 418–423.
9. *Hernesniemi J*: Penetrating cranio-cerebral gunshot wounds in civilians. *Acta Neurochir* 1979; 49: 199–205.
10. *Graham T, Williams F, Harrington T, Spetzler R*: Civilian gunshot wounds to head; a prospective study. *Neurosurgery* 1990; 27: 696–700.
11. Hashimoto T, Nakamura N, Richard KE, Frowein RA: Primary brain stem lesions caused by closed head injuries. *Neurosurg Rev* 1993; 16: 291–298.
12. *Vukic M, Negovetic L, Kovac D, Ghajar J, Glavic Z, Gopcevic A*: The effect of implementation of guidelines for the management of severe head injury on patient treatment and outcome. *Acta Neurochir* 1999; 141: 1203–1208.
13. *Hesdorffer DC, Ghajar J, Iacono L*: Predictors of compliance with the evidence-based guidelines for traumatic brain injury care: a survey of United States trauma centers. *J Trauma* 2002; 52: 1202–1209.
14. Brain Trauma Foundation; American Association of Neurological Surgeons; Congress of Neurological Surgeons. Guidance for the management of severe traumatic brain injury. *J Neurotrauma* 2007; 24: 1–106.
15. *Haddad S, Arabi Y*: Critical care management of severe traumatic brain injury in adults. *Scand J Trauma Resusc Emerg Med* 2012; 20: 12. doi: 10.1186/1757-7241-20-12.

## Adres do korespondencji:

Katarzyna Śmiłowska, MD  
 Department of Anaesthesiology,  
 Intensive Care and Emergency Medicine in Zabrze,  
 Medical University of Silesia in Katowice  
 Plac Medyków 1, 41–200 Sosnowiec, Poland  
 e-mail: kasia.smilowska@gmail.com

Otrzymano: 13.08.2014 r.

Zaakceptowano: 6.03.2015 r.