

Lichtenstein tension-free hernia repair: its background and evolution with focus on avoiding postherniorrhaphy chronic pain

Parviz K. Amid

Department of Surgery, David Geffen School of Medicine at UCLA and Lichtenstein Hernia Institute at UCLA, Los Angeles, USA

Videosurgery and other miniinvasive techniques 2009; 4 (1): 26–31

Abstract

To circumvent the degenerative nature of inguinal hernias and adverse effect of suture line tension, the Lichtenstein tension-free hernioplasty began in 1984, and evolved (between 1984 and 1988) to a procedure that is now considered the gold standard of hernia repair by the American College of Surgeons. Confirmed by hundreds of publications, from sources interested in hernia surgery, rate of recurrence and postoperative chronic pain is less than 1%. When the key principles of the procedure are respected the rate of recurrence and chronic inguinodynia after the Lichtenstein tension-free hernia repair is a fraction of one percent.

Key words: Lichtenstein tension-free hernia repair, postherniorrhaphy inguinodynia, meshoma.

Today, understanding the role of reduced ratio of collagen type I and III in the pathogenesis of groin hernias has led to a new grasp of the pathology of groin hernias and the causes of their surgical failure. These changes lead to weakening of the fibroconnective tissue of the groin and development of inguinal hernias. To use this already defective tissue, especially under tension, is a violation of the most basic principles of surgery.

This type of thinking inspired investigators to develop a host of prosthetic materials. Many were associated with disastrous complications related to rejection and infection. Usher is credited with popularizing the use of polypropylene mesh which has been in use since the mid 1950s with a negligible complication rate.

In 1984, metabolic nature of inguinal hernia and adverse effect of suture line tension prompted our group to popularize routine use of mesh, coining the term “tension-free” hernioplasty.

In 1989, Nyhus removed the fear of infection and rejection when he stated “My concerns relative to the potentially increase incident of infection or rejection of the polypropylene mesh have not been warranted to date” [1].

Lichtenstein tension-free hernioplasty began in 1984. In the late 1980s, analyzing data from our own hernia registry, we established a set of key principles (outlined below), employed them with satisfactory results, and reported in 1993 [2].

As the name implies, the main goal of the tension-free hernioplasty is achieving a repair that is free of all tension, not only on the operating table, where the patient is in a supine position but also postoperatively despite adverse effects, such as the intra-abdominal pressure gradient and contraction of the mesh.

Drye’s study of intra-abdominal pressure [3] demonstrated a mean pressure of 8 cm H₂O with the subject supine. When the subject was standing,

Address for correspondence

Parviz K. Amid, MD, FACS, FRCS, Department of Surgery, David Geffen School of Medicine at UCLA and Lichtenstein Hernia Institute, 5901 W. Olympic Blvd., Suite 207, Los Angeles, CA 90036, USA, phone: 1 323 938 5173, fax: 1 323 938 4863, e-mail: pamid@onemain.com

intra-abdominal pressure in the pelvic area increased to 12 cm H₂O. Various activities, such as straining and vomiting, increased pressure to more than 80 cm H₂O. Increased intra-abdominal pressure causes forward protrusion of the lower abdominal wall, particularly the transversalis fascia. If the repair is to be completely tension-free, then forward protrusion of the transversalis fascia must be addressed.

According to our laboratory and clinical studies reported in 1996 [4], the mesh contracts by approximately 20% in both directions after implantation, a conclusion confirmed by Klinge *et al.* in 1998 [5]. In order to circumvent the adverse effects of increased intra-abdominal pressure and shrinkage of mesh, avoid recurrence, and postoperative chronic pain, the following principles have been the integral parts of our operation since 1988.

1. Use a large sheet of mesh that will extend approximately 2 cm medial to the pubic tubercle, 4-5 cm above the Hesselbach's triangle, and 6-7 cm lateral to the internal ring. We suggest using a 7 × 15 cm sheet of mesh for easy handling, then trimming 3-4 cm from its lateral side (Figure 1).
2. Cross the tails of the mesh behind the spermatic cord to avoid recurrence lateral to the internal ring (Figure 1). Suturing the tails together in a parallel position, without crossing, is a known cause of recurrence in the internal ring area.
3. Secure the upper edge of the mesh to the internal oblique aponeurosis (not to the muscle for reason stated under number 5) with two interrupted

sutures and the lower edge of the mesh to the inguinal ligament using a continuous suture with no more than 3-4 passes. Fixation of the mesh prevents movement, folding, and wadding of the mesh (meshoma) [6] which can cause chronic pain and recurrence of the hernia.

4. Keep the mesh slightly relaxed, to counteract the forward protrusion of the transversalis fascia when the patient stands up from the intra-operative supine position, and to compensate for contraction of the mesh.
5. Visualize and protect the ilioinguinal, iliohypogastric, and genital nerves throughout the operation. The iliohypogastric nerve can be identified easily, while the external oblique aponeurosis is being separated from the internal oblique layer in order to fix the mesh to the internal oblique aponeurosis (Figure 2). Because of a natural anatomic cleavage, separation of these two layers from each other is easy, fast, and bloodless. The most vulnerable part of the iliohypogastric nerve is its intramuscular segment (Figure 3), which runs along the lower edge of the internal oblique muscle (the so-called conjoint tendon) [2, 7]. Passing a suture through the internal oblique muscle to approximate this layer to the inguinal ligament (during tissue approximation repairs) to a plug (during mesh plug repair) or to the upper edge of the mesh (during Lichtenstein repair) is liable to injure the intramuscular portion of the iliohypogastric

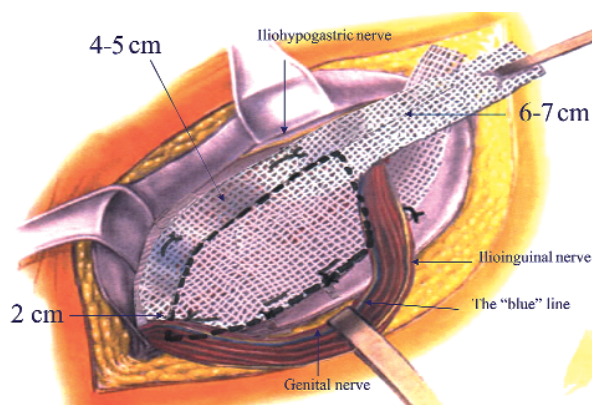


Figure 1. Extension of the mesh beyond the boundary of the inguinal floor, and identification of ilioinguinal, iliohypogastric and genital nerves

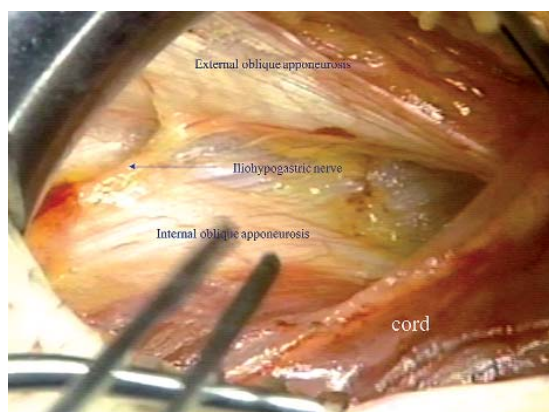


Figure 2. Separation of the external oblique aponeurosis from the internal oblique layer to visualize the internal oblique aponeurosis and the iliohypogastric nerve

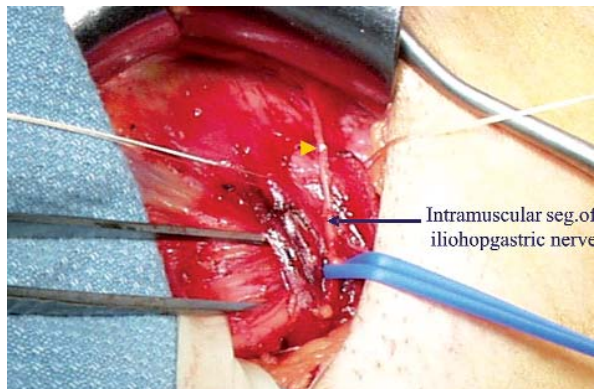


Figure 3. The internal oblique muscle is splitted (the edges of the split are retracted by the whit sutures) below the point of emergence of the iliohypogastric nerve (pointed to by the arrow) to show the course of the intramuscular segment of the nerve

nerve with the needle or entrap the nerve with the suture. The genital nerve is protected by keeping the easily visible blue external spermatic vein (the blue line) with the spermatic cord while it is being lifted from the inguinal floor (Figure 4). The ilioinguinal nerve can easily be located over the spermatic cord and covered and protected by the investing fascia of the internal oblique fascia (Figure 5). Manipulating and lifting the nerve from its natural bed damages its protective fascia and increase the risk of perineural fibrosis and chronic postherniorrhaphy inguinodynia. If a nerve is in the way of the repair it can be resected with ligation of the cut ends in order to avoid formation of traumatic neuroma.

Technique of the operation

Following is a step-by-step description of the Lichtenstein tension-free repair, as practiced by us since 1988. Local anesthesia is preferred for all reducible adult inguinal hernias [8]. It is safe, simple, effective, economical, and without the side effects of nausea, vomiting, and urinary retention. Furthermore, local anesthesia administered prior to making the incision produces a prolonged analgesic effect via inhibition of the build-up of local nociceptive molecules. Several safe and effective anesthetic agents are currently available. Our choice, however, is a 50 : 50 mixture of 1% lidocaine (Xylocaine, Astra Pharmaceuticals, L.P., Wayne, PA, USA) and 0.5% bupivacaine (Marcaine,

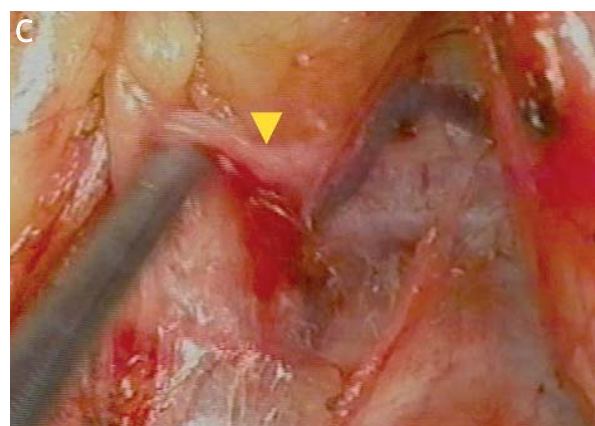
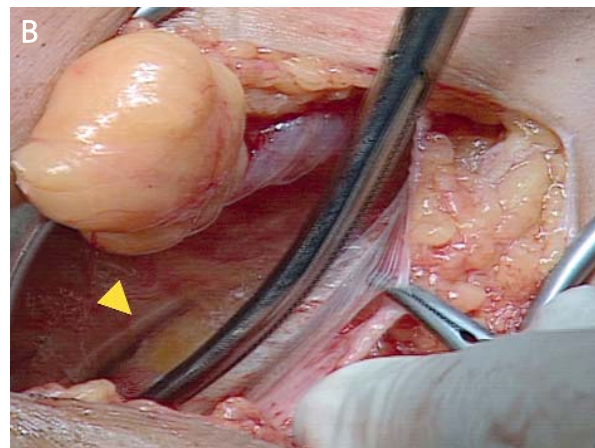
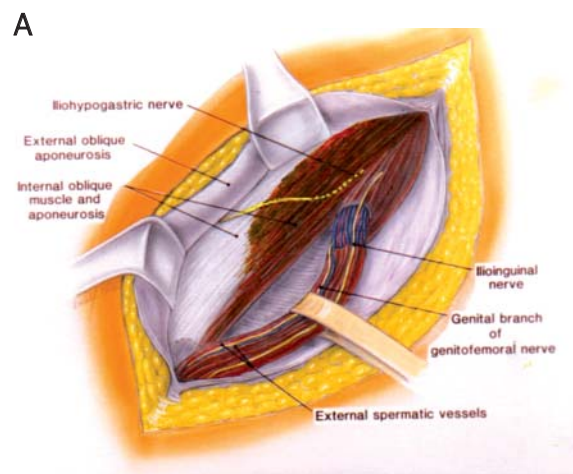


Figure 4. Genital branch of the genitofemoral nerve above the easily visible “blue” line of the external spermatic vein covered and protected by the investing fascia of the internal oblique muscle (pointed to by the arrow)

Abbott Laboratories, North Chicago, IL, USA), with 1/200,000 epinephrine. A 5-6 cm skin incision, which starts from the pubic tubercle and extends laterally within the Langer's line, gives an excellent access for extension of the mesh 2 cm or more medial to the pubic tubercle. After skin incision, the external oblique aponeurosis is opened and its lower leaf freed from the spermatic cord. The upper leaf of the external oblique is then freed from the underlying internal oblique muscle and aponeurosis for a distance of 3-4 cm above the inguinal floor. The anatomic cleavage between these two layers is avascular and the dissection can be done rapidly and non-traumatically. High separation of these layers has a dual benefit, as it visualizes the iliohypogastric nerve and creates ample space for insertion of a sufficiently wide sheet of mesh that can overlap the internal oblique by 3-4 cm above the upper margin of the inguinal floor. The cord with its cremaster covering is separated from the floor of the inguinal canal and the pubic bone for a distance of about 2 cm beyond the pubic tubercle.

The anatomic plane between the cremasteric sheath and the attachment of the rectus sheet to the pubic bone is avascular, so there is no risk of damaging the testicular blood flow. When lifting the cord, care should be taken to include the ilioinguinal nerve, external spermatic vessels, and the genital nerve with the cord. This assures that the genital nerve, which is always in juxtaposition to the external spermatic vessels, is preserved.

To explore the internal ring for indirect hernia sacs, the cremasteric sheath is incised longitudinally at the deep ring. Complete stripping and excision of the cremasteric fibers is unnecessary, and can result in injury to the nerves, small blood vessels, and vas deferens. Furthermore, it can lead to the testicle hanging too low.

Indirect hernial sacs are freed from the cord to a point beyond the neck of the sac and inverted without ligation. Due to mechanical pressure and ischemic changes, ligation of the highly or innervated peritoneal sac leads to short term postoperative pain. If the internal ring is too large it can be tightened with a simple suture. To minimize the risk of postoperative ischemic orchitis, complete nonsliding scrotal hernia sacs are transected at the midpoint of the canal, leaving the distal section in place. However, the anterior wall of the distal sac is incised to prevent postoperative hydrocele formation.

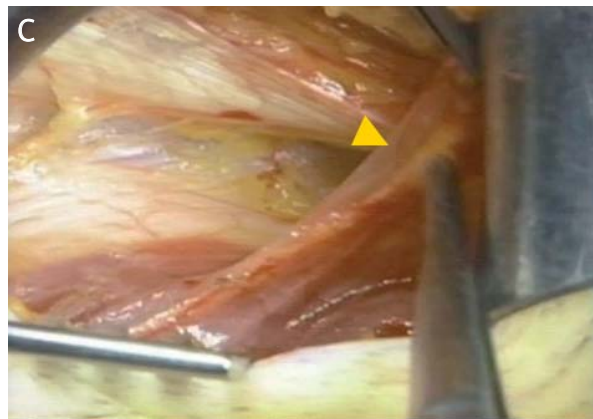
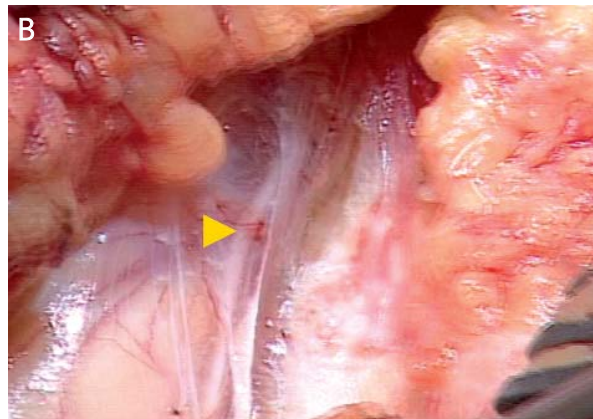
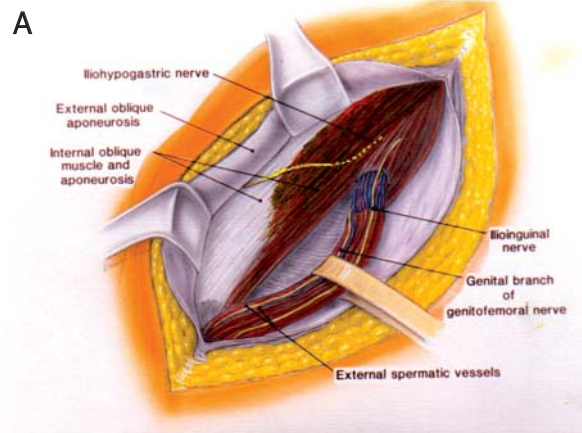


Figure 5. Ilioinguinal nerve covered and protected by the investing fascia of the internal oblique muscle (pointed to by the arrow)

In the event of direct hernias, if large, the sacs are inverted with an absorbable suture. A thorough exploration of the groin is necessary to rule out the coexisting intraparietal (interstitial), low-lying Spigelian or femoral hernias. The femoral ring is

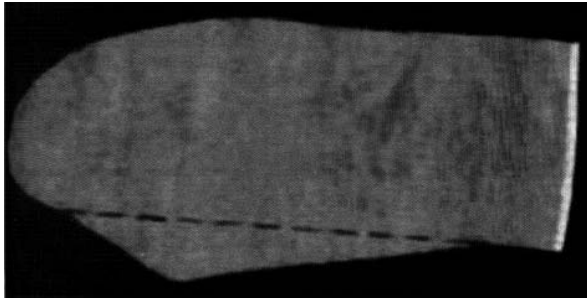


Figure 6. The triangular downward extension of the mesh. The edge of the triangle is sutured to the ligament of Cooper and the broken line is sutured to the inguinal ligament

routinely evaluated *via* Bogros' space through a small opening in the canal floor. A sheet of 7 × 16 cm of mesh is used. We prefer monofilamented polypropylene meshes because their surface texture promotes fibroplasia and their monofilamented structure does not perpetuate or harbor infection. The standard shape of the mesh resembles the tracing of a footprint. On the medial end the mesh has a sharp curve (on the great toe side of the foot), which fits in the sharp angle between the inguinal ligament and anterior rectus sheath and a wider curve (on the little toe side of the foot), which spreads over the rectus sheath. With the cord retracted cephalad, the lower medial corner of the mesh is placed over and extended medial to the pubic tubercle, overlapping the pubic tubercle by 1.5 to 2.0 cm. Extension of the mesh medial to the pubic tubercle, which is a critical step of the operation, is easy to achieve and only requires starting the skin incision from the pubic tubercle (for easy access to the pubic tubercle) and separation of the spermatic cord and lateral crus of the external ring from the rectus sheath. The medial corner of the mesh is then sutured to the rectus sheath above the pubic bone carefully avoiding the periosteum of the bone. This suture is continued (as a continuous suture) to attach the lower edge of the mesh to the inguinal ligament up to a point just lateral to the internal ring. Suturing the mesh beyond this point is unnecessary and could injure the femoral nerve. If there is a concurrent femoral hernia, the mesh is tailored to have a triangular extension from its lower edge (Figure 6). The edge of the dropped down triangle is then sutured to the Cooper's ligament (after opening the posterior wall, reducing the femoral hernia and

exposing the Cooper's ligament) and the body of the mesh is sutured to the inguinal ligament [9].

A slit is made at the lateral end of the mesh, creating two tails, a wide one (two thirds) above and a narrower (one third) below. The upper wide tail is grasped with a hemostat and passed toward the head of the patient from underneath the spermatic cord; this positions the cord between the two tails of the mesh (Figure 1).

The wider upper tail is crossed and placed over the narrower one and held with a hemostat. With the cord retracted downward and the upper leaf of the external oblique aponeurosis retracted upward, the upper edge of the patch is sutured in place with two interrupted absorbable sutures, one to the rectus sheath and the other to the internal oblique aponeurosis (not the internal oblique muscle), just lateral to the internal ring.

Using a single non-absorbable monofilamented suture, the lower edges of each of the two tails are fixed to the inguinal ligament just lateral to the completion knot of the lower running suture.

The excess patch on the lateral side is trimmed, leaving at least 5 cm of mesh lateral to the internal ring. This is tucked underneath the external oblique aponeurosis, which is then closed over the cord with an absorbable suture. Fixation of the tails of the mesh to the internal oblique muscle, lateral to the internal ring, is unnecessary and could result in entrapment of the ilioinguinal nerve with the fixation suture.

Twenty-one years after the introduction of the tension-free hernioplasty in 1984, the operation has been thoroughly evaluated in large series and has been universally accepted, and in fact it is considered the gold standard of hernia repairs by the American College of Surgeons. The world-wide effectiveness of the operation (success rate of approximately 1%) in the hands of nonexperts is virtually the same as its reported efficacy (success rate of 1% or less in the hands of experts).

References

1. Nyhus LM. The preperitoneal approach and iliopubic tract repair of inguinal hernia. In: Nyhus LM, Condon RE (eds.) *Hernia*. 3rd ed. J.B. Lippincott Company, Philadelphia, Pennsylvania 1989; 154-77.
2. Amid PK. Causes, prevention, and surgical treatment of postherniorrhaphy neuropathic inguinodynia: triple neurectomy with proximal end implantation. *Hernia* 2004; 8: 343-9.
3. Drye JC. Intraperitoneal pressure in the human. *Surg Gynecol Obstet* 1948; 87: 472-5.

4. Amid PK. Classification of biomaterials and their related complications in abdominal wall hernia surgery. *Hernia* 1997; 1: 12-9.
5. Klinge U, Klosterehalfen B, Müller M, et al. Shrinking of polypropylene mesh in vivo: An experimental study in dogs. *Eur J Surg* 1998; 164: 965-9.
6. Amid PK. Radiologic images of meshoma: a new phenomenon after prosthetic repair of abdominal wall hernias. *Arch Surg* 2004; 139: 1297-8.
7. Amid PK, Hiatt JR. New understanding of the causes and surgical treatment of postherniorrhaphy inguinodynia and orchalgia. *J Am Coll Surg* 2007; 205: 381-5.
8. Amid PK, Shulman AG, Lichtenstein IL. Local anesthesia for inguinal hernia repair step-by-step procedure. *Ann Surg* 1994; 220: 735-7.
9. Amid PK. Lichtenstein tension-free hernioplasty: Its inception, evolution, and principles. *Hernia* 2004; 8: 1-7.