

# Brachytherapy in accelerated partial breast irradiation (APBI) – review of treatment methods

Janusz Skowronek, MD, PhD, Ass. Prof., Magdalena Wawrzyniak-Hojczyk, MD, Kinga Ambrochowicz, MD

Brachytherapy Department, Greater Poland Cancer Center, Poznań, Poland

## Abstract

Breast conserving surgery (BCS) with following radiotherapy (EBRT) of the conserved breast became widely accepted in the last decades as the treatment of early invasive breast cancer. In an early stage of breast cancer, research has shown that the area requiring radiation treatment to prevent cancer from local recurrence is the breast tissue that surrounds the area where the initial cancer was removed. Accelerated partial breast irradiation (APBI) is an approach that treats only the lumpectomy bed with 1-2 cm margin, rather than the whole breast and as a result allows accelerated delivery of the radiation dose in four to five days. Published results of APBI are very promising. It is evident that APBI will play a role in the management of a selected group of early breast cancer. We discuss current status, indications, technical aspects and recently published results of APBI using different brachytherapy techniques.

J Contemp Brachyther 2012; 4, 3: 152-164

DOI: 10.5114/jcb.2012.30682

**Key words:** APBI, balloon, brachytherapy, breast cancer, interstitial.

## Purpose

Breast cancer is the most frequently detected cancer in women in developed countries and its incidence ranges from 25% to 30% of all cancers in women. Average age of breast cancer patients range between 45 and 65, however, in recent years is noticeable that the average age of incidence tend to lower [1]. With the prevalence of screening and increasing awareness of the disease, more and more women may be treated with breast-conserving surgery (BCS) with a complementary external beam radiation therapy (EBRT) and tumor's bed dose increasing ('boost'). Results of conservative treatment supplemented by radiation therapy are as good as the results obtained after mastectomy [2-6]. Further advances in radiotherapy techniques and knowledge of the biology of breast cancer, in addition to the standard methods of combination therapy (WBRT and 'boost'), increases the application of APBI as a radical treatment in particular cases [7-11]. This method of radiation therapy is used in a selected group of patients in the early stages of the disease [3,12-17]. The main reason for APBI introduction was the assumption that it leads to obtain an equivalent local control rates with less toxicity of treatment compared with whole breast irradiation technique (EBRT) after BCS in the selected group of patients. The results of studies comparing the effectiveness of BCS + WBRT and APBI have shown that a very large percentage of local recurrence (more than 80-90%) occurs in the immediate vicinity of the original location of the tumor.

This was the primary cause for the use of brachytherapy alone after breast-conserving therapy in a strictly selected group of patients. The advantage of this method is also shorter time of treatment from 5-7 weeks (WBRT + boost), to 4-5 days of APBI. It is supposed to be capable of reducing the rate of complications: radiation-induced reactions, telangiectasia and fibrosis. Due to increasing use of APBI methods we present the most recent reports on this subject. We describe the treatment techniques, principles of patient selection for this method, the results of treatment and current recommendations of GEC-ESTRO (Groupe Européen de Curietherapie - European Society for Therapeutic Radiology and Oncology), ABS (American Brachytherapy Society) and ASTRO (American Society for Therapeutic Radiology), three major world societies of radiation oncologists.

## Rationale for use of APBI

The results of studies examining the efficacy of BCS followed by whole breast radiotherapy (WBRT) showed that a very large percentage of local recurrence arises in the immediate vicinity of the original location of the tumor (Fig. 1). At least five prospective randomized studies examining the percentage of local recurrence after radiotherapy the whole breast were published and it was found that 69% to 90% recurrences occur in immediate vicinity of the primary tumor (Table 1). In other studies, the percentage of recurrences in other quadrants than in being treated or contralateral

**Address for correspondence:** Janusz Skowronek, MD, PhD, Ass. Prof., Brachytherapy Department, Greater Poland Cancer Center, Poznań, Poland, 15 Garbary Street, 61-866 Poznań, phone: +48 61 885 08 18, +48 602 61 85 38, fax: +48 61 885 08 34, ✉ e-mail: janusz.skowronek@wco.pl

Received: 14.08.2012

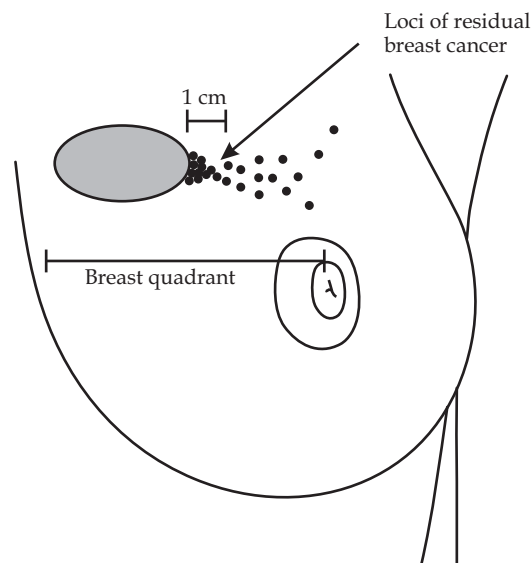
Accepted: 06.09.2012

Published: 27.09.2012

breast was 0.9% to 3.5% in prospective studies and 2% to 5% in retrospective studies (Table 2). This was the basic cause for the use of brachytherapy alone after BCS treatment in a strictly selected group of patients [5,10,15,26-28]. Another advantage of this method pointed out by many authors is also shortening the treatment duration from 5-7 weeks (conventional EBRT) to 4-5 days, what, particularly for working women, living far away from the cancer center and older patients is important. Offeresen *et al.* [29] in the summary pointed out that in the U.S. socio-economic factors affect the type of surgery – poorer women (eg, paying a lower insurance premium) and/or living far from the radiotherapy center choose mastectomy, even after qualifying for the BCS. In some areas, up to 25% of older women after BCS are not irradiated from these reasons. After examination of 175 000 patients with early breast cancer (SEER database) it was found that in 1992-2003 the percentage of BCS increased from 41% to 60%, while the proportion of patients irradiated after BCS decreased from 79% to 71%. Undoubtedly it affects the increased risk of local recurrences after BCS. Similar conclusions were reached by Njeh *et al.* [30] – in this article, they exchanged the factors affecting to decide RT: convenience, accessibility, cost, distance from the center of RT, lack of transportation, lack of social support, movement difficulties of patients doctor bias, age of the patient and fear of radiation. Also in Japan, only about 70% of patients are treated with radiotherapy after BCS, for similar reasons as in the U.S.

**Indications for APBI**

Recommendations of the American Brachytherapy Society (ABS) and the American Society of Breast Surgeons (ASBS) on the qualifications for APBI are shown in Table 3 [31], while the GEC-ESTRO (Groupe Européen de Curie-thérapie European Society for Therapeutic Radiology and Oncology) recommendations are posted in Table 4 [32].



**Fig. 1.** Schematic location of the satellite foci of cancer in the immediate vicinity of the primary tumor

**Contraindications for APBI**

It lists: clinical stage III or IV, no evaluation of surgical margins, presence of extensive intraductal component (EIC), Paget's disease, infiltration or other changes in skin, present contralateral breast cancer (or in the past), previous others cancers (within 5 years from eligibility for the study) with the exception of skin cancer and 0 or I stage FIGO cervical cancer (previous), pregnancy or lactation period, connective tissue disorders, collagen diseases, genetic or metabolic proceeding with hypersensitivity to radiation such as Ataxia teleangiectasia or similar, disorder or mental diseases, anticipated difficulties with carrying out brachytherapy [3,6,10,11].

**Table 1.** Spatial pattern of ipsilateral breast relapse (IBTR) in patients enrolled in randomised trials testing the effect of whole breast radiotherapy [11]

Trial (time of primary treatment)	Median follow-up (range)	Recurrence number/ Total number of patients	Pattern of IBTR
NSABP B-06 (1976-1984) [12]	39 (5-95) months	110 (1108)	86% within or close to the quadrant of the index cancer 14% more diffuse within the breast
Uppsala-Orebro (1981-1988) [13]	10 years	57 (381)	69% in the surgical field 3.6% in the cuticular scar 3.6% in the skin overlying the surgical field 23.6% in the breast parenchyma outside the field of surgery
Ontario Clinical Oncology Group (1984-1989) [14]	43 months	131 (837)	86% (83% with RT) at the site of primary surgery
Milan III (1987-1989) [15]	9 years	75 (579)	85% (84% with RT) in the scar area 15% (16% with RT) in other quadrants
SweBCG 91-RT (1991-1997) [16]	5 years	104 (1178)	90% in the same quadrant as the previous tumour 10% in other quadrants

**Table 2.** Spatial pattern of ipsilateral breast relapse (IBTR) in patients treated with breast conserving surgery plus whole breast radiotherapy [11]

Authors, studies	Median follow-up (range)	Local recurrence rate (%)	Recurrence rate outside of treated quadrant (%)	Recurrence rate in second breast (%)
<b>Retrospective clinical trials (BCS + EBRT)</b>				
Kurtz <i>et al.</i> [17]	11 (5-24) years	11	2	6
Freedman <i>et al.</i> [18]	5 years	3	1	3
	10 years	7	2	7
	15 years	13	6	13
Krauss <i>et al.</i> [19]	5 years	2	0.1	4
	10 years	7	2	9
	15 years	10	3	12
Veronesi <i>et al.</i> [20]	8.5 years	6.8	1.4	5
<b>Prospective trials (BCS + EBRT)</b>				
NSABP B-06 [21]	39 (5-95) months	2.7	0.7	9.4
Uppsala-Orebro trial [13]	10 years	8.5	2.1	10.5
Scottish trial [22]	5.7 years	5.8	1.4	1
Milan III [15]	9 years	5.4	1.3	3.4
NSABP B-21 [23]	8 years	9.3	2.3	5.4
SweBCG 91-RT [16]	61 (10-98) months	4.4	1.1	3.4
GBCSG trial [24]	5.9 years	4.2	1	2.1
ABCSG study 8 [25]	53.8 months	0.5	0.1	0.5

BCS – Breast Conserving Surgery, EBRT – External Beam Radiation Therapy

**Table 3.** American Brachytherapy Society and American Society of Breast Surgeons selection criteria and the Eligibility Criteria for NSABP B-39/RTOG 0413 Trial [31]

	ABS	ASBS	NSABP B-39 RTOG 0413
<b>Age</b>	≥ 50	≥ 45	≥ 18
<b>Histology</b>	unifocal, invasive ductal cancer	invasive ductal cancer or DCIS	invasive adenocarcinoma or DCIS
<b>Tumor size</b>	≤ 3 cm	≤ 3 cm	≤ 3 cm
<b>Surgical margins</b>	negative microscopic margins	negative microscopic margins	negative microscopic margins
<b>Number of involved lymph nodes</b>	0	0	0–3

### APBI techniques

In APBI currently are applied several techniques: 1) Interstitial brachytherapy (HDR, PDR, permanent implants); 2) Brachytherapy using the balloons (Mammosite, Contura); 3) Hybrid brachytherapy devices (SAVI applicator); 4) External beam radiotherapy (3D, IMRT); 5) IORT (intraoperative radiotherapy) with electrons or X-rays. Below we will discuss the basic principles of brachytherapy techniques.

### Patient qualification for brachytherapy techniques

Before preparing the treatment plan, a careful evaluation of tumor size and location should be made (clinical ex-

amination, mammography, ultrasonography (US), magnetic resonance (MRI)), determination of the stage of disease according to TNM and detailed histopathological examination should be performed. In the course of conservative treatment it is advisable to leave 4 to 6 clips on the border of tissue removed in the axis of anterior-posterior, posterior-medial, sagittal, up and down, which will facilitate the preparation of the brachytherapy treatment plan. Clipping of tumor bed is considered by many authors as the most precise factor determining the accuracy of brachytherapy. In the treatment planning using BT are also helpful: description of surgical procedures specifying the location of the scar in relation to the tumor bed, postoperative mammography, occasionally X-ray image of the tumor bed or postoperative ultrasound.

**Table 4.** GEC-ESTRO recommendations on patient selection for accelerated partial-breast irradiation [32]

Characteristic	A) Low-risk group – good candidates for APBI	B) Intermediate-risk group – possible candidates for APBI	C) High-risk group – contraindication for APBI
Age	> 50 years	40-50 years	< 40 years
Histology	IDC, mucinous, tubular, medullary, and colloid cc.	IDC, ILC, mucinous, tubular, medullary, and colloid cc	–
ILC	not allowed	not allowed	–
Associated LCIS	allowed	allowed	–
DCIS	not allowed	allowed	–
HG	any	any	–
Tumour size	pT1-2 (< 30 mm)	pT1-2 (< 30 mm)	pT2 (> 30 mm), pT3, T4
Surgical margin	negative (> 2 mm)	negative, but close (< 2 mm)	positive
Multicentricity	unicentric	unicentric	multicentric
Multifocality	unifocal	multifocal (limited within 2 cm of the index lesion)	multifocal (> 2 cm from the index lesion)
EIC	not allowed	not allowed	present
LVI	not allowed	not allowed	present
ER, PR status	any	any	–
Nodal status	pN0 (SLNB or ALND*)	pN1mi, pN1a (by ALND*)	pNx; PpN2a (4 or more positive nodes)
Neoadjuvant chemotherapy	not allowed	not allowed	if used

APBI – accelerated partial-breast irradiation; IDC – invasive ductal carcinoma; ILC – invasive lobular carcinoma; LCIS – lobular carcinoma in situ; DCIS – ductal carcinoma in situ; HG – histologic grade; EIC – extensive intraductal component; LVI – lympho-vascular invasion; ER – estrogen receptor; PR – progesterone receptor; SLNB – sentinel lymph node biopsy \*ALND – axillary lymph node dissection (at least 6 nodes pathologically examined)

### Interstitial multicatheter brachytherapy

Currently, two brachytherapy techniques are used in breast cancer brachytherapy: HDR (high dose rate) and PDR (pulsed dose rate). Some clinical studies are published on using permanent implants ( $I^{125}$ ,  $Pd^{103}$ ) [33,34].

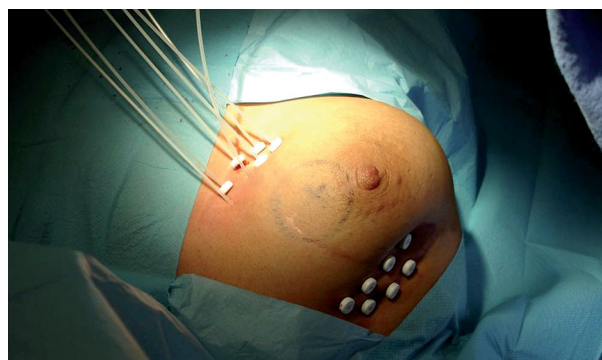
#### Techniques

##### Perioperative application of catheters

Brachytherapy using interstitial applicators can be performed in two ways. Perioperative brachytherapy involves the assumption of flexible applicators during surgery in place of the tumor bed. In this method, BT is applied immediately during BCS. The advantage of a perioperative technique is a need for only one general anesthesia (implantation of applicators takes place during surgery), resulting in reducing overall treatment time and the ability to precisely determining the location of the tumor visible during surgery. Throughout lumpectomy/quadrantectomy, the surgeon provides surgical clips (should be 6) to determine the tumor bed (the clips are helpful later in treatment planning). Applying of applicators requires precision, experience and basic knowledge in the field of radiation from the surgeon. The limitation of perioperative “boost” is the lack of the final histopathological examination - the risk of incorrect BT qualification can be leveled by precise clinical staging before procedure, intraoperative histological examination and the necessary implementation of the Sentinel-Lymph-Node Biopsy (SNL). The irradiated area is limited to the surgical bed with 1-1.5 cm margin depending on technique.

##### Application of catheters after BCS

Applicators are often implanted after healing of the surgical scar and after receiving the final histopathological diagnosis in 2-4 weeks after surgery. Radiation oncologist inserts applicators after visualization of the tumor bed using X-ray (the location of surgical clips) and ultrasound (in general) or local anesthesia (depending on the experience of the center). Location of applicators on the skin with subcutaneous tissue and part of the breast is anesthetized with lidocaine or Xylocaine (2%) solution, while analgesics are intravenously administered. General anesthesia involves standard procedures. After determining the shape and position of the tumor bed, the correct template and number of planes is selected, as well as the distance between the ap-



**Fig. 2.** Interstitial brachytherapy for breast cancer – implantation of 7 flexible applicators attached to the skin with buttons, the tumor bed localized by ultrasound



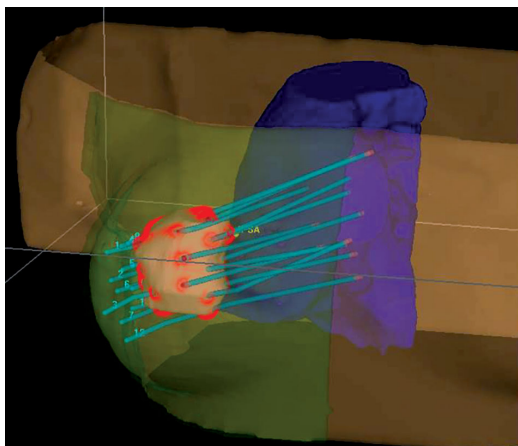


Fig. 3. Example of 3D treatment plan for breast cancer, indicating target, applicators, and critical organs (plan prepared by Oncentra Prostate®)

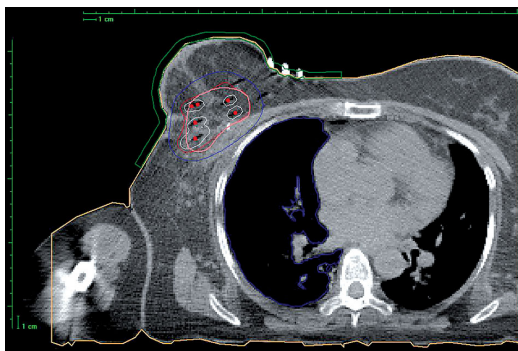


Fig. 4. The distribution of dose (isodoses) obtained after the preparation of the treatment plan, target CT cross-sections performed every 2-3 mm

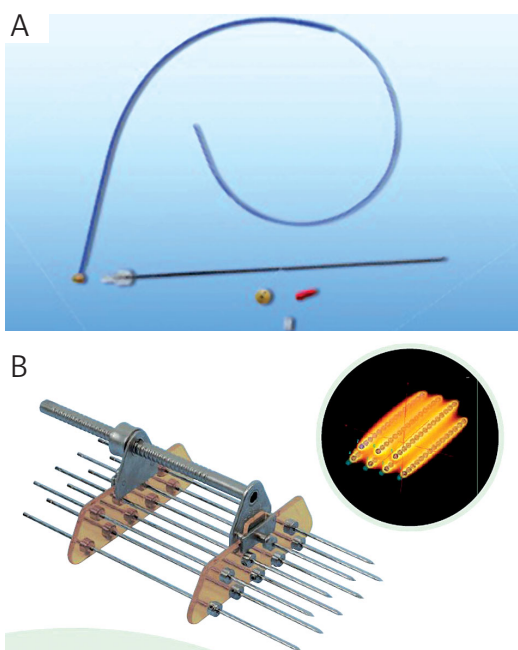


Fig. 5. Examples of applicators used in interstitial brachytherapy, A) from Varian Medical Systems (Breast Catheter Kits), B) from Nucletron Applicator Guide (Breast Template Set "Rabbit")

plicators and the active length for stepping source. The number of implanted applicators has to be determined individually, depending on breast size, location of the tumor bed and type of surgery (tumorectomy, quadrantectomy). Frequently it is from 7 to over a dozen. Figure 2 shows images of applicators implanted in a patient with breast cancer after quadrantectomy, covering the upper external quadrant. Figures 3-5 present examples of treatment plan and applicators used in interstitial BT.

#### *Balloon brachytherapy (MammoSite, Contura) and hybrid SAVI applicators*

This technique was intended to reduce the technical difficulties associated with EBRT treatment planning and application of many interstitial applicators. The balloon applicator consists of a silicone balloon catheter, containing a channel for filling the balloon and 1 to 8 channels to introduce radioisotope (Figs. 6A-B, 7A-B). SAVI applicator does not include a balloon, but only applicators to adapt to the shape of the box (Figs. 8A-D). Balloon technique in principle is applicable in APBI without WBRT after surgery. HDR sources are used in this technique. Balloon applicators may be placed in the bed of the tumor during the BCS (rarely) or 2-4 weeks after surgery with the help of ultrasound. Previously published results suggest a satisfactory treatment outcome (as measured by the percentage of local failure) and good cosmetic results (80% to 93% of patients) [36-43]. So far, we do not have randomized studies comparing this technique treatment with interstitial BT.

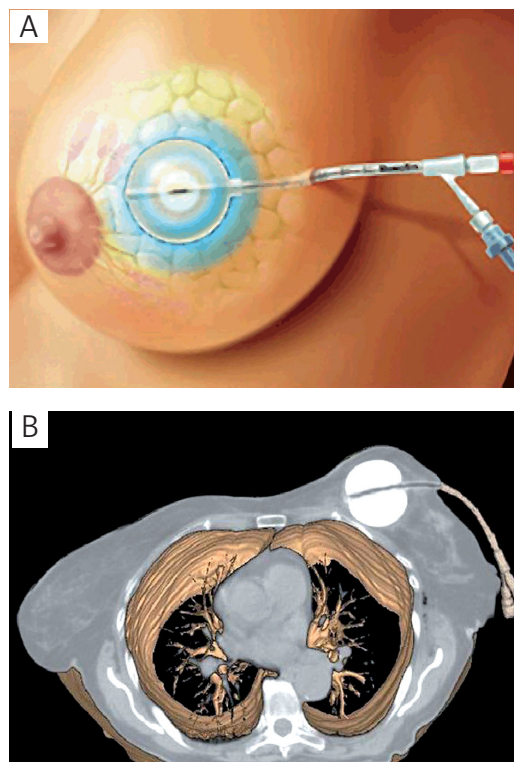
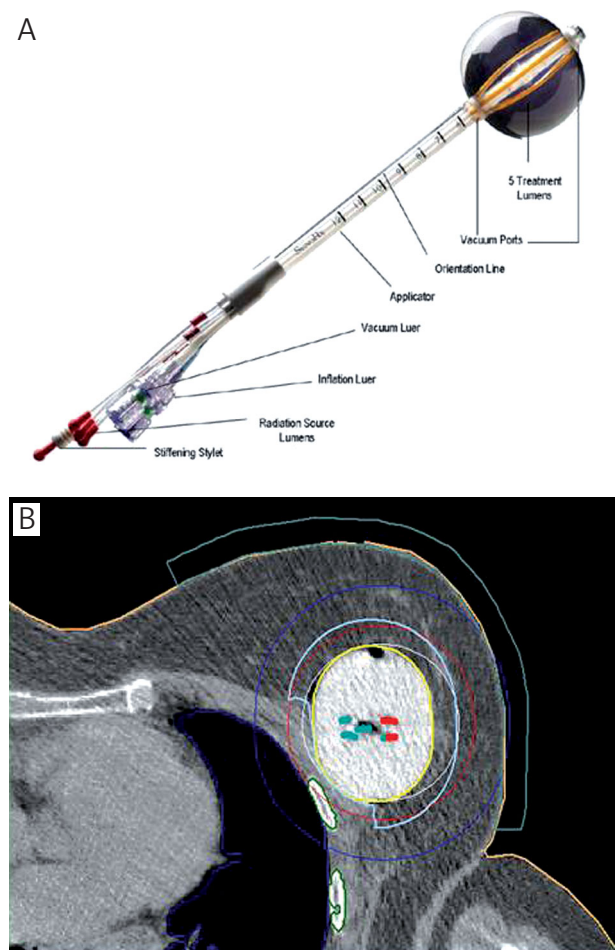


Fig. 6. A) MammoSite device used in balloon brachytherapy (Hologic®, Marlborough). B) MammoSite balloon applicator in CT cross section with the indication of lung



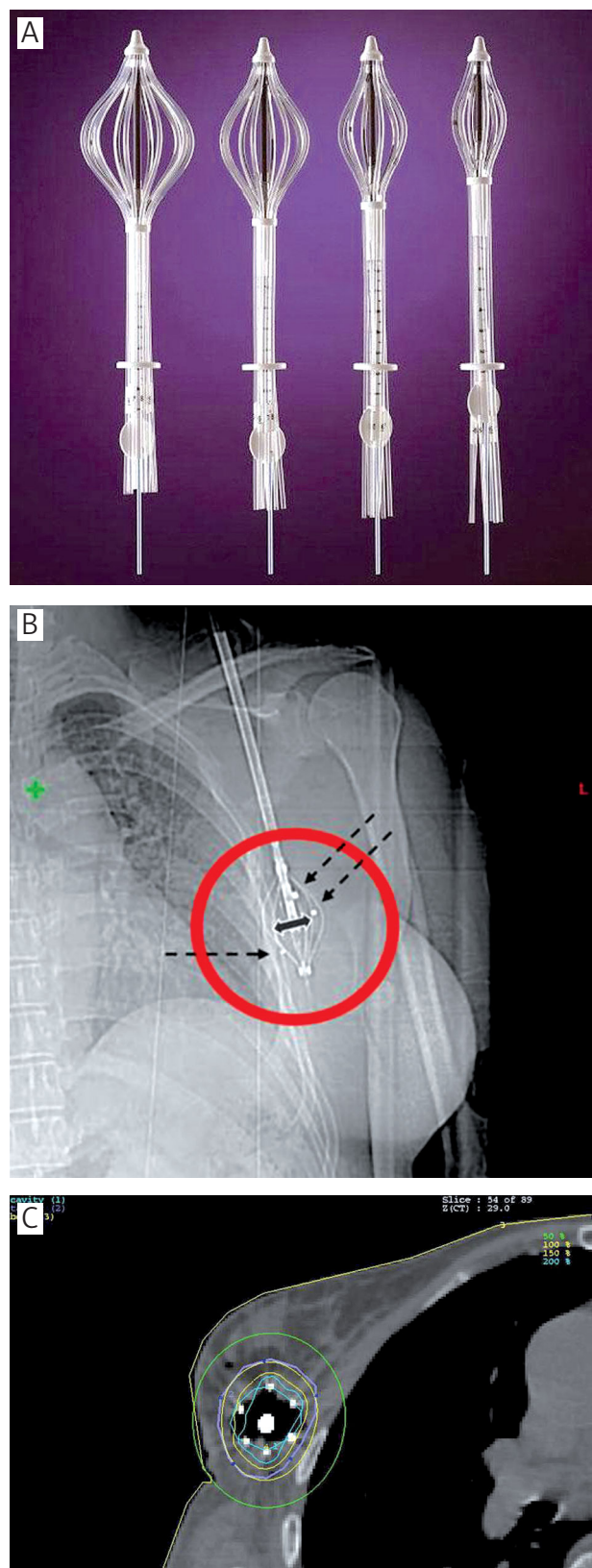
**Fig. 7.** A) Contura balloon applicator (SenoRx®) [30]. B) Contura balloon applicator on CT section with the distribution of isodoses, 5 channels for iridium visible

The possible response will bring the results of Phase III Trial (NSABP B-39/RTOG 0413) conducted by the National Surgical Adjuvant Breast and Bowel Project (NSABP) and the Radiation Therapy Oncology Group (RTOG). The objective of this trial is to compare the results of different treatment methods: WBRT, APBI with MammoSite or multicatheter interstitial BT 3D EBRT in stage 0, I and II of breast cancer [38].

Balloon brachytherapy was developed as an alternative to interstitial brachytherapy. Interstitial brachytherapy requires the experience in setting up many interstitial applicators, while using balloon brachytherapy is simpler in the application. Cosmetic results after balloon brachytherapy techniques seem to be very acceptable [37,40,43-45] with a high rate of satisfactory or excellent results. To achieve such results, the proper selection of patients (large breasts, central location of the primary tumor) is significant.


**Technique**

The balloon applicator consists of a silicone balloon with catheter to fill the balloon with fluid and 1 to 8 channels, where a radioactive source is placed. For the greater precision, in most centers using this method, the balloon is fixed



**Fig. 8.** A) Applicator SAVI (Strut Adjusted Volume Implant) with expanded channels (Cianna Medical®) [30]. B) SAVI applicator X-ray images showing surgical clips (arrows) [35]. C) SAVI applicator, a balloon with a visible isodoses [35]





**Fig. 9.** A) Axxent Electronic Brachytherapy System, the control unit (Xoft®) [30]. B) Axxent Electronic Brachytherapy System, X-ray source HDR (Xoft®) [30]. C) Axxent Electronic Brachytherapy System, a balloon applicator (Xoft®) [30]

in the operating room under ultrasonography. Then the applicator is fluid-filled to a volume strictly adhering to the walls of the tumor bed. Afterwards, a cross-section CT is made in order to prepare a treatment plan. Target (CTV) in-

cludes the volume of the balloon with a margin of 1 cm. Critical organs include the skin and lungs. In this technique HDR sources are used.

### Doses

The most common treatment schemas of APBI techniques are: 1) fraction dose of 3.4 Gy two times daily with an interval of 6 hours, 10 fractions in 5 days to a total dose of 34 Gy; 2) fraction dose of 4 Gy two times daily – 8 fractions to 32 Gy; 3) fraction dose of 4.3 Gy two times daily – 7 fractions to 30.1 Gy [31,32].

### Electronic brachytherapy [30]

A platform for delivering HDR brachytherapy radiation has been developed that involves the electronic generation of kV X-rays instead of using a radioactive source. The Axxent X-Ray Source manufactured by Xoft, Inc. was approved by the FDA for the treatment of breast cancer in January 2006 (Figs. 9A-C). The Xoft Axxent produces X-rays ranging from 20 to 50 kV, although only the 50 kV X-ray setting is used in breast brachytherapy. Using the 50 kV setting, the average energy of the X-rays is 28 keV; the radial dose function lies between those of  $^{125}\text{I}$  and  $^{103}\text{Pd}$  sources [46]. The Xoft Axxent Electronic Brachytherapy source is used in conjunction with a balloon applicator. The disposable source is intended to be used for a maximum of 10 fractions. Testing of the inter-source consistency performed by Rivard *et al.* shows that individual sources produce predictable energy spectra, anisotropy functions and radial dose functions. As such, independent dosimetric verification is not necessary for each source. Instead, prior to each treatment, a single measurement of the source air-kerma strength is the only requirement [46].

The low energy photons emitted from the kV brachytherapy source (KVB) have a limited range that obviates the need for a shielded radiation vault. This expands the settings in which the source could be used and may increase the availability of PBI. Additionally, the difference in photon energy between a KVB source and an  $^{192}\text{Ir}$  source has dosimetric implications. Dickler *et al.* found that the %V90 and %V100 do not appear to differ between KVB and MammoSite, demonstrating that KVB offers comparable target volume coverage. Due to its rapid dose fall-off, KVB provides a mean ipsilateral lung %V30 of 1.1% compared to 3.7% for MammoSite. Using KVB, the volume of the PTV receiving 200% of the prescription dose slightly exceeded the volume associated with an increased risk of fat necrosis in a previous study by Wazer *et al.* [44]. Similarly, a phantom study of KVB by Smitt *et al.* found that in order to achieve 90% coverage of the PTV, the V200 varied from 16 to 22 cm<sup>3</sup> [48]. These figures are far higher than those of MammoSite and approach the dose-volume constraints that have been shown to be correlated with fat necrosis in studies of interstitial multicatheter brachytherapy [49]. However, it is unclear if dosimetric parameters that predict fat necrosis in multicatheter procedures are applicable to balloon applicator procedures. The effect of chemotherapy on the development of fat necrosis also remains to be clarified.

**Table 5.** Comparison of APBI techniques – from Offersen [29] and Sarin [50]

	3D EBRT	Interstitial brachytherapy HDR, LDR, PDR	MammoSite	Target, 50 kV X-rays	IORT, electrons
Coverage of target	best	good	good	good	good
Thickness of cavity wall irradiated	PTV = tumor bed + 20-25 mm often 5 mm to field edge from PTV	1-2 cm	dose prescribed to 1 cm from surface of applicator	dose prescribed to 1 mm from surface of applicator. 5-7 Gy 10 mm from applicator	dose prescribed to 90% isodose line. 80% isodose at 13 mm (3 MeV) – 24 mm (9 MeV)
Dose homogeneity	best	fair	fair	fair	fair
Sparing of normal breast/other organs	least	good	good	best	varies with location
Skin dose	least	least	variable	least (can shield)	least
Technical feasibility for various size, shape or location of cavity	suitable for virtually all cases	not suitable if inadequate tissue or near axilla	not suitable for large/irregular cavities, or at the periphery of the breast	not suitable for large/irregular cavities, or at the periphery of the breast	not suitable for tumors near brachial plexus/axilla or skin
Expertise required	average	high	average	high	very high
Potential for wide spread use	very good	fair	very good	fair	limited
Main drawback	relatively higher dose to normal tissue and breathing motion	adequacy of target coverage in some cases and wider applicability	cavity shape and size. Although easy to use, stringent QA is required. Skin dose may be high	very limited depth irradiated; cavity shape and size, histology not available	wider applicability. Histology not available, based on quadrantectomy

**Table 6.** Results of recent clinical experience with interstitial brachytherapy with more than 5 years follow-up [30]

Author	No of cases	Follow up interval (years)	Technique	Scheme	Total dose (Gy)	5-year LR (%)	Good/Excellent cosmesis
Strnad <i>et al.</i> [51]	274	5.25	PDR/HDR	PDR – 0.6 Gy/h HDR – 4 Gy × 8 fr.	PDR = 50 Gy HDR = 32 Gy	2.9%	90%
Antonucci <i>et al.</i> [52]	199	9.6	LDR/HDR	LDR – 0.52 Gy/h × 96 h HDR – 4 Gy × 8 fr. HDR – 3.4 Gy × 10 fr.	LDR = 50 Gy HDR = 32 Gy HDR = 34 Gy	5%	99%
Johansson <i>et al.</i> [53]	50	7.2	PDR	HDR – 50 Gy/5 d	50 Gy	4%	56%
Arthur <i>et al.</i> [54]	99	7	LDR/HDR	LDR – 3.5 Gy/5 d HDR – 3.4 Gy × 10 fr.	45 Gy (LDR) 34 Gy (HDR)	4%	n/a
Polgar <i>et al.</i> [55]	128	6.8	HDR	HDR – 5.2 Gy × 7 fr.	36.4 Gy	4.7%	77%
King <i>et al.</i> [56]	51	6.25	LDR/HDR	LDR – 4 d HDR – 4 Gy × 8 fr.	45 Gy (LDR) 32 Gy (HDR)	3.9%	75%
Otto <i>et al.</i> [57]	274	5.25	PDR/HDR	PDR – 5 d, 0.6 Gy/h HDR – 4 Gy × 8 fr.	49.8 Gy (PDR) 32 Gy (HDR)	2.9%	92%
Polgar <i>et al.</i> [58]	45	11.1	HDR	HDR – 4.33 Gy × 7 fr. HDR – 5.2 Gy × 7 fr.	30.3 Gy 36.4 Gy	4.4%	78%

LR – local recurrence; HDR – high dose rate; LDR – low dose rate; PDR – pulsed dose rate; n/a – data not available; h – hours, d – days; fr. – fractions

## Results of APBI

Comparison of different APBI techniques is posted in Table 5 [29,50]. Clinical results of APBI after various treat-

ment techniques are presented in tables. Table 6 presents the results of interstitial brachytherapy, Tables 7, 8 – results of balloon brachytherapy.



**Table 7.** Some of the recent clinical experience with MammoSite [29]

Institution	APBI technique	No. of cases	Follow-up (years)	Inclusion criteria and definition of target	Ipsilateral breast recurrence
American Society of Breast Surgeons, MammoSite Breast Brachytherapy Trial [59-64]	34 Gy/10 fr/5-7 d	1255	2.5	> 45 years, T6 2 cm, N0, negative margins, ductal only, applicator placement < 10 weeks postoperative, cavity P3 cm in one dimension, no EIC,	2 years – 1.11%, 3 years – 1.79%
Texas Cancer Clinic San Antonio [65]	34 Gy/10 fr/5-7 d	67	1.1	≥ 45 years, T < 3 cm, N0, negative margins, lumpectomy cavity 3-6 cm	NA
Kaiser Permanente Los Angeles Medical Center [66,67]	34 Gy/10 fr/5-7 d	51	1.3	≥ 45 years, T6 2 cm, N0, ductal only, negative margins	0
Rush University Medical Center, Chicago [68,69]	34 Gy/10 fr/5-7 d	78	2.2	≥ 45 years, T < 3 cm, N0, negative margins	7.1%
Medical University of South Carolina [70]	32 Gy/10 fr/5-7 d	37 (7 with DCIS)	0.5	any age, pTis-pT2N1, negative margins	NA
Tufts New England [71,72]	34 Gy/10 fr/5-7 d	38	1.4	any age, T < 3 cm, ductal and DCIS, N0 (solitary nodal micrometastasis accepted), negative margins > 1 mm	NA
European MammoSite trial [73,74]	34 Gy/10 fr/5-7 d	28	1.2	≥ 60 years, T ≤ 2 cm, ductal only, grade 1/2, margins > 5 mm, ER +, balloon-skin distance > 7 mm, lumpectomy cavity > 3 cm, no EIC	0

EIC – extensive intraductal component; DCIS – ductal carcinoma in situ; ER – estrogen receptor; PR – progesterone receptor; N/A – data not available; d – days; fr – fractions

**Table 8.** Local recurrences after MammoSite [31]

Trial	No. of cases	Follow-up (months)	Local recurrences rate (%)
ASBS TRIAL [75]	1440	30	1.04
Tufts/Medical College Virginia/Rhode Island [71]	28	19	0
St. Vincent Cancer Center [66]	31	11	0
Rush University Medical Center [76]	70	26	5.7
Kaiser Permanente [49]	40	13	0
Medical University South Carolina [74]	90	24	2.2
ASBS DCIS TRIAL [77]	191	7	0
William Beaumont [68]	80	22	2.5
European TRIAL [73]	44	14	0
International TRIAL [78]	23	20	0
Western Pennsylvania Hospital [79]	55	24	3.6
Oscar Lambret Center [69]	25	13	0

**Table 9.** Rates of good and excellent cosmesis after MammoSite brachytherapy [31]

Institution/Study	Number of patients	Follow-up (months)	Good or excellent cosmesis (%)
ASBS registry trial [63]	1449	30	94
FDA trial [75]	36	65	81
Tufts/medical college of Virginia/Rhode Island [46]	28	19	93
St. Vincent's cancer center [66]	31	11	86
Rush university medical center [76]	30	26	93
Kaiser permanente [49]	40	13	97
Medical University of South Carolina [74]	90	24	90
ASBS DCIS trial [77]	191	7	94
William Beaumont [68]	80	22	88
European trial [73]	44	14	75
International trial [78]	18	20	67
Oscar Lambret center [69]	25	13	84

**Table 10.** Cosmesis and complications after APBI with interstitial brachytherapy [29]

Institution	Technique	Number of patients	Follow-up	Cosmesis and complications
The William Beaumont Hospital, USA [49,80-82]	HDR 32-34 Gy/8-10 fr/4-5 days LDR 50 Gy, 96 hours	199	5.7 years (LR), 6.4 years (cosmesis)	7% acute infection, 4% late infection, 11% fat necrosis at $\geq 5$ years <sup>a</sup> , good/excellent cosmesis <sup>b</sup> in > 90%
Ochsner Clinic, USA [83]	HDR 32-34 Gy/8-10 fr/4-5 days LDR 45 Gy, 4 days	50	6.3 years	cosmesis scored at median 20 months: 22% grade I/II compl., 8% grade III compl., 75% had an excellent/good cosmesis <sup>a</sup> , all based on <sup>a</sup>
Ochsner Clinic, USA [84]	HDR 32-34 Gy/8-10 fr/4-5 days LDR 45 Gy, 4 days	99	2.7 years	late grade III tox. 18% (LDR) and 4% (HDR), no late grade IV tox., all based on <sup>a</sup>
London Regional Cancer Center, Ontario [85]	HDR 37.2 Gy/10 fr/5 days	39	7.6 years	median overall cosmetics score 89%, 13% had fat necrosis <sup>a</sup> , all based on <sup>a</sup>
Tufts New England [44,86-88]	HDR 34 Gy/10 fr/5 days	75	6.1 years	cosmesis <sup>a</sup> , excellent/good/fair-poor: 67%/24%/9% at last follow-up, late skin tox. <sup>c</sup> grad. 1/2/3 77%, 19%, 4%, late subcutaneous tox. grad. 1/2/3/4 55%, 15%, 12%, 18%
Tufts New England [89]	LDR 50, 55, and 60 Gy	48	1.9 years	very good/excellent cosmesis 91.8%, 12.5% perioperative complications, 25% had fibrosis, 8% moderate to severe fibrosis, based on <sup>a</sup>
Tufts New England [90]	HDR 34 Gy/10 fr/5 days	32	7 years	18% had fat necrosis > 5 years, 35.7% moderate to severe subcutaneous fibrosis > 5 years, 89% excellent cosmesis at 5 years, toxicity based onc, fibrosis > 5 years
University of Kansas [91]	LDR 20-25 Gy	24	3.9 years	cosmesis good to excellent in 100%, no late complications, based on <sup>a</sup>
Guys Hospital, London [92,93]	LDR 55 Gy, 5 days	27	6 years	cosmesis good to excellent in 83%, no fibrosis, based on <sup>a</sup>
Guys Hospital, London [94]	LDR 45 Gy, 4 days	49	6.3 years	abnormal breast in 58%, based on <sup>a</sup>
National Institute of Oncology, Hungary [95,96]	HDR 30.3-36.4 Gy/7 fr/4 days	45	6.8 years	cosmesis excellent/good in 84.4%, fat necrosis 20%, $\geq$ grade 2 late radiation reaction 26.7%, based on <sup>b</sup>
National Institute of Oncology, Hungary [55,97]	HDR 36.4 Gy/7 fr/4 days ( $n = 88$ ) or ERBT 50 Gy/25 fr ( $n = 40$ )	126	5.5 years	excellent to good in 81.2% (HDR) and 70% (electrons), based on <sup>b</sup> , 4-year actuarial fat necrosis 36.5% (HDR) and 17.7% (electrons), based on institutional scheme
Erlangen, Germany [57,98-100]	HDR (36%) 32 Gy/8 fr/5 days; PDR (64%) 49.8 Gy in 83 consecutive fractions of 0.6 Gy each hour/5 days	274	2.7 years	cosmesis excellent to good in 94%, acute toxicity in 6.6%, fat necrosis 4.7%, breast tissue fibrosis in 19.3% and telangiectasia in 12.8%, scoring based on <sup>b,c,d</sup>

Number of patients refers to patients diagnosed with invasive cancer<sup>a</sup>; Cosmesis scored according to institutional guidelines: <sup>b</sup> Cosmesis scored according to Harvard criteria [101]; <sup>c</sup> Skin and subcutaneous toxicity scored according to Radiation Therapy Oncology Group (RTOG)/Eastern Cooperative Oncology Group system [102]; <sup>d</sup> Acute and late side effects based on LENT SOMA [103]

### Cosmetic effect

Cosmetic results after brachytherapy techniques seem to be very satisfactory. Draws attention a high rate of satisfactory or excellent results. Essential to achieve such results is a proper selection of patients (large breasts, the central location of the primary tumor).

The tables below provide a summary of cosmetic results after using the balloon brachytherapy and interstitial brachytherapy (Tables 9, 10).

### Conclusions

The percentage of local recurrence and the cosmetic results are an important argument for the choice of APBI brachytherapy technique. Based on available results from prospective clinical trials where excellent results in selected groups of patients are achieved, it seems reasonable to use of APBI outside clinical trials in selected cases. These is a conclusion also of GEC-ESTRO Breast Cancer Working Group [32]. Strict criteria for selecting patients with early

breast cancer group (low-risk group) and systematic quality control procedures (QA) must be preserved. These recommendations may be an indication for physicians and patients to choose an APBI techniques.

## References

- Jassem J (ed.). Rak sutka. *Springer-PWN*, Warszawa 1998 [in Polish].
- Clarke DH, Vicini F, Jacobs H et al. High dose rate brachytherapy for breast cancer. In: Nag S (ed.). High dose rate brachytherapy: A textbook. *Armonk Futura Publishing Company Inc.*, New York 1994, pp. 321-329.
- Gerbaulet A, Potter R, Mazeron J-J et al. (eds.). The GEC ESTRO Handbook of Brachytherapy. *ESTRO*, Brussels 2002.
- Sauer G, Strnad V, Kurzeder C et al. Partial Breast Irradiation after Breast-Conserving Surgery. *Strahlenther Onkol* 2005; 181: 1-8.
- Makarewicz R (ed.). Brachyterapia HDR. *Via Medica*, Gdańsk 2004 [in Polish].
- Polgar C, Major T, Somogyi A et al. Sole brachytherapy after breast conserving surgery: 4-years results of a pilot study and initial findings of a randomized Phase III trial (abstract). *Radiother Oncol* 2000; 55 (suppl. 1): 31.
- Vicini F, Kini VR, Chen P. Brachytherapy of the tumour bed alone after lumpectomy in selected patients with early stage breast cancer treated with breast conserving therapy. *J Surg Oncol* 1999; 70: 30-40.
- Kuske RR, Bolton JS, Mc Kinnon MP et al. 6.5-year results of a prospective phase II trial of wide volume brachytherapy as the sole method of breast irradiation in Tis, T1, T2, No1 breast cancer (abstract). *Radiother Oncol* 2000; 55 (suppl.1): 2.
- Johansson B, Kalsson L, Liljegren G et al. PDR brachytherapy as the sole adjuvant radiotherapy after breast conserving surgery of T1-T2 breast cancer (abstract). In: Program & Abstracts. 10<sup>th</sup> International Brachytherapy Conference, Madrid, Nucletron 2000, pp. 127.
- Niwińska A. Postępy w radioterapii: napromienianie części gruczołu piersiowego (Partial Breast Irradiation – PBI) u chorych na raka piersi po operacji oszczędzającej. *Nowotwory* 2003; 6: 643-647 [in Polish].
- Mannino M, Yarnold J. Accelerated partial breast irradiation trials: Diversity in rationale and design. *Radiother Oncol* 2009; 91: 16-22.
- Fisher ER, Sass R, Fisher B et al. Pathologic findings from the National Surgical Adjuvant Breast Project (protocol 6). II. Relation of local breast recurrence to multicentricity. *Cancer* 1986; 57: 1717-1724.
- Liljegren G, Holmberg L, Bergh J et al. 10-Year results after sector resection with or without postoperative radiotherapy for stage I breast cancer: a randomized trial. *J Clin Oncol* 1999; 17: 2326-2333.
- Clark RM, Whelan T, Levine M et al. Randomized clinical trial of breast irradiation following lumpectomy and axillary dissection for node-negative breast cancer: an update. Ontario Clinical Oncology Group. *J Natl Cancer Inst* 1996; 88: 1659-1664.
- Veronesi U, Marubini E, Mariani L et al. Radiotherapy after breast-conserving surgery in small breast carcinoma: long-term results of a randomized trial. *Ann Oncol* 2001; 12: 997-1003.
- Malmstrom P, Holmberg L, Anderson H et al. Breast conservation surgery, with and without radiotherapy, in women with lymph node-negative breast cancer: a randomized clinical trial in a population with access to public mammography screening. *Eur J Cancer* 2003; 39: 1690-1697.
- Kurtz JM, Amalric R, Brandone H et al. Local recurrence after breast conserving surgery and radiotherapy. Frequency, time course, and prognosis. *Cancer* 1989; 63: 1912-1917.
- Freedman GM, Anderson PR, Hanlon AL et al. Pattern of local recurrence after conservative surgery and whole-breast irradiation. *Int J Radiat Oncol Biol Phys* 2005; 61: 1328-1336.
- Krauss DJ, Kestin LL, Mitchell C et al. Changes in temporal patterns of local failure after breast-conserving therapy and their prognostic implications. *Int J Radiat Oncol Biol Phys* 2004; 60: 731-740.
- Veronesi U, Marubini E, Del Vecchio M et al. Local recurrences and distant metastases after conservative breast cancer treatments: partly independent events. *J Natl Cancer Inst* 1995; 87: 19-27.
- Fisher B, Anderson S, Bryant J et al. Twenty-year follow-up of a randomized trial comparing total mastectomy, lumpectomy, and lumpectomy plus irradiation for the treatment of invasive breast cancer. *N Engl J Med* 2002; 347: 1233-1241.
- Forrest AP, Stewart HJ, Everington D et al. Randomized controlled trial of conservation therapy for breast cancer: 6-year analysis of the Scottish trial. *Scottish Cancer Trials Breast Group. Lancet* 1996; 348: 708-713.
- Fisher B, Bryant J, Dignam JJ et al. Tamoxifen, radiation therapy, or both for prevention of ipsilateral breast tumor recurrence after lumpectomy in women with invasive breast cancers of one centimeter or less. *J Clin Oncol* 2002; 20: 4141-4149.
- Winzer KJ, Sauer R, Sauerbrei W et al. Radiation therapy after breast conserving surgery; first results of a randomized clinical trial in patients with low risk of recurrence. *Eur J Cancer* 2004; 40: 998-1005.
- Potter R, Gnant M, Kwasny W et al. Lumpectomy plus tamoxifen or anastrozole with or without whole breast irradiation in women with favorable early breast cancer. *Int J Radiat Oncol Biol Phys* 2007; 68: 334-340.
- Resch A, Fellner C, Mock U et al. Locally recurrent breast cancer: pulse dose rate brachytherapy for repeat irradiation following lumpectomy a second chance to preserve the breast. *Radiology* 2002; 225: 713-718.
- Sauer G, Strnad V, Kurzeder C et al. Partial Breast Irradiation after Breast-Conserving Surgery. *Strahlenther Onkol* 2005; 181: 1-8.
- Weed DW, Edmundson GK, Vicini FA et al. Accelerated partial breast irradiation: A dosimetric comparison of three different techniques. *Brachytherapy* 2005; 4: 121-129.
- Offersen BV, Overgaard M, Kroman N et al. Accelerated partial breast irradiation as part of breast conserving therapy of early breast carcinoma: A systematic review. *Radiother Oncol* 2009; 90: 1-13.
- Njeh CF, Saunders MW, Langton CM. Accelerated Partial Breast Irradiation (APBI): A review of available techniques. *Radiation Oncol* 2010, 5: 90; doi:10.1186/1748-717X-5-90.
- Strauss JB, Dickler A. Accelerated partial breast irradiation utilizing balloon brachytherapy techniques. Review of partial breast brachytherapy. *Radiother Oncol* 2009; 91: 157-165.
- Polgár C, Van Limbergen E, Pötter R et al. Patient selection for accelerated partial-breast irradiation (APBI) after breast-conserving surgery: Recommendations of the Groupe Européen de Curiethérapie – European Society for Therapeutic Radiology and Oncology (GEC-ESTRO) breast cancer working group based on clinical evidence. *Radiother Oncol* 2010; 94: 264-273.
- Keller B, Sankrecha R, Rakovitch E et al. A permanent breast seed implant as partial breast radiation therapy for early-stage patients: a comparison of palladium-103 and iodine-125 isotopes based on radiation safety considerations. *Int J Radiat Oncol Biol Phys* 2005; 62: 358-365.
- Pignol J-P, Rakovitch E, Keller B et al. Tolerance and acceptance results of a palladium-103 permanent breast seed implant phase I/II study. *Int J Radiat Oncol Biol Phys* 2009; 73: 1482-1488.



35. Scanderbeg DJ, Yashar C, Rice R et al. Clinical implementation of a new HDR brachytherapy device for partial breast irradiation. *Radiother Oncol* 2009; 90: 36-42.
36. Weed DW, Edmundson GK, Vicini FA et al. Accelerated partial breast irradiation: A dosimetric comparison of three different techniques. *Brachytherapy* 2005; 4: 121-129.
37. Dickler A, Kirk MC, Chu J et al. The MammoSite™ breast brachytherapy applicator: A review of technique and outcomes. *Brachytherapy* 2005; 4: 130-136.
38. Perera F, Chisela F, Engel M et al. Method of localization and implantation of the lumpectomy cavity for high dose rate brachytherapy after conservative surgery for T1 and T2 breast cancer. *Int J Radiat Oncol Biol Phys* 1995; 31: 4959-4966.
39. Kirk M, Hsi WC, Dickler A et al. Surface Optimization Technique for MAMMOSITE Breast Brachytherapy Applicator. *Int J Radiat Oncol Biol Phys* 2005; 62: 366-372.
40. Kini V. Balloon breast brachytherapy – review of current data. *Brachytherapy* 2005; 4: 181-182.
41. Forszpaniak J. Balloon brachytherapy: how I do it. *Nowotwory* 2004; 1: 11-14.
42. Keisch M, Arthur DW. Current perspective on the MammoSite Radiation Therapy System – A balloon breast brachytherapy applicator. *Brachytherapy* 2005; 4: 177-180.
43. White J. MammoSite and accelerated partial breast irradiation: Rethinking one-size-fits-all breast irradiation after lumpectomy. *Brachytherapy* 2005; 4: 183-185.
44. Wazer DE, Kaufman S, Cuttino L et al. Accelerated Partial Breast Irradiation: An Analysis Of Variables Associated With Late Toxicity And Long-Term Cosmetic Outcome After High-Dose-Rate Interstitial Brachytherapy. *Int J Radiat Oncol Biol Phys* 2006; 64: 489-495.
45. De la Rochefordière A, Abner AL, Silver B et al. Are cosmetic results following conservative surgery and radiation therapy for early breast cancer dependent on technique? *Int J Radiat Oncol Biol Phys* 1992; 23: 925-917.
46. Rivard MJ, Davis SD, DeWerd LA et al. Calculated and measured brachytherapy dosimetry parameters in water for the Xofigo X-Ray Source: an electronic brachytherapy source. *Med Phys* 2006; 33: 4020-4032.
47. Dickler A, Patel RR, Wazer D. Breast brachytherapy devices. *Expert Rev Med Devices* 2009; 6: 325-333.
48. Smitt MC, Kirby R. Dose-volume characteristics of a 50-kV electronic brachytherapy source for intracavitary accelerated partial breast irradiation. *Brachytherapy* 2007; 6: 207-211.
49. Chen PY, Vicini FA, Benitez P et al. Longterm cosmetic results and toxicity after accelerated partial-breast irradiation: a method of radiation delivery by interstitial brachytherapy for the treatment of early-stage breast carcinoma. *Cancer* 2006; 106: 991-999.
50. Sarin R. Partial-breast treatment for early breast cancer: emergence of a new paradigm. *Nat Clin Pract Oncol* 2005; 2: 40-47.
51. Strnad V, Hildebrandt G, Potter R et al. Accelerated Partial Breast Irradiation: 5-Year Results of the German-Austrian Multicenter Phase II Trial Using Interstitial Multicatheter Brachytherapy Alone After Breast-Conserving Surgery. *Int J Radiat Oncol Biol Phys* 2011; 80: 17-24.
52. Antonucci JV, Wallace M, Goldstein NS et al. Differences in patterns of failure in patients treated with accelerated partial breast irradiation versus whole-breast irradiation: a matched-pair analysis with 10-year follow-up. *Int J Radiat Oncol Biol Phys* 2009; 74: 447-452.
53. Johansson B, Karlsson L, Liljegren G et al. Pulsed dose rate brachytherapy as the sole adjuvant radiotherapy after breast-conserving surgery of T1-T2 breast cancer: first long time results from a clinical study. *Radiother Oncol* 2009; 90: 30-35.
54. Arthur DW, Winter K, Kuske RR et al. A Phase II trial of brachytherapy alone after lumpectomy for select breast cancer: tumor control and survival outcomes of RTOG 95-17. *Int J Radiat Oncol Biol Phys* 2008; 72: 467-473.
55. Polgar C, Fodor J, Major T et al. Breast-conserving treatment with partial or whole breast irradiation for low-risk invasive breast carcinoma 5-year results of a randomized trial. *Int J Radiat Oncol Biol Phys* 2007; 69: 694-702.
56. King TA, Bolton JS, Kuske RR et al. Long-term results of wide-field brachytherapy as the sole method of radiation therapy after segmental mastectomy for T(is,1,2) breast cancer. *Am J Surg* 2000; 180: 299-304.
57. Ott OJ, Hildebrandt G, Potter R et al. Accelerated partial breast irradiation with multi-catheter brachytherapy: Local control, side effects and cosmetic outcome for 274 patients. Results of the German-Austrian multi-centre trial. *Radiother Oncol* 2007; 82: 281-286.
58. Polgar C, Major T, Fodor J et al. Accelerated partial-breast irradiation using high-dose-rate interstitial brachytherapy: 12-year update of a prospective clinical study. *Radiother Oncol* 2010; 94: 274-279.
59. Keisch M, Vicini F, Kuske RR et al. Initial clinical experience with the MammoSite breast brachytherapy applicator in women with early-stage breast cancer treated with breast-conserving therapy. *Int J Radiat Oncol Biol Phys* 2003; 55: 289-293.
60. Chao KK, Vicini FA, Wallace M et al. Analysis of treatment efficacy, cosmesis, and toxicity using the MammoSite breast brachytherapy catheter to deliver accelerated partial-breast irradiation: the William Beaumont hospital experience. *Int J Radiat Oncol Biol Phys* 2007; 69: 32-40.
61. Zannis V, Beitsch P, Vicini F et al. Descriptions and outcomes of insertion techniques of a breast brachytherapy balloon catheter in 1403 patients enrolled in the American Society of Breast Surgeons MammoSite breast brachytherapy registry trial. *Am J Surg* 2005; 190: 530-538.
62. Richards GM, Berson AM, Rescigno J et al. Acute toxicity of high-dose-rate intracavitary brachytherapy with the MammoSite applicator in patients with early-stage breast cancer. *Ann Surg Oncol* 2004; 11: 739-746.
63. Vicini F, Beitsch P, Quiet C et al. Three-year analysis of treatment efficacy, cosmesis, and toxicity by the American society of breast surgeons MammoSite breast brachytherapy registry trial in patients treated with accelerated partial breast irradiation (APBI). *Cancer* 2008; 112: 758-766.
64. Vicini FA, Beitsch PD, Quiet CA et al. First analysis of patient demographics, technical reproducibility, cosmesis and early toxicity: results of the American society of surgeons MammoSite breast brachytherapy registry trial. *Cancer* 2005; 104: 1138-1148.
65. Sadeghi A, Prestidge B, Lee J et al. Evaluation of the surface radiation dose and dose gradient in early stage breast cancer using high-dose-rate brachytherapy MammoSite applicator. *Brachytherapy* 2006; 5: 230-234.
66. DiFronzo LA, Tsai PI, Hwang JM et al. Breast conserving surgery and accelerated partial breast irradiation using the MammoSite system. *Arch Surg* 2005; 140: 787-794.
67. Tsai PI, Ryan M, Meek K et al. Accelerated partial breast irradiation using the MammoSite device: early technical experience and short-term clinical follow-up. *Am Surg* 2006; 72: 929-934.
68. Chen S, Dickler A, Kirk M et al. Patterns of failure after MammoSite brachytherapy partial breast irradiation: a detailed analysis. *Int J Radiat Oncol Biol Phys* 2007; 69: 25-31.
69. Dickler A, Kirk MC, Choo J et al. Cosmetic outcome and incidence of infection with the MammoSite breast brachytherapy applicator. *Breast J* 2005; 11: 306-310.

70. Harper JL, Jenrette JM, Vanek KN et al. Acute complications of MammoSite brachytherapy: a single institution's initial clinical experience. *Int J Radiat Oncol Biol Phys* 2005; 61: 169-174.
71. Shah NM, Tenenholz T, Arthur D et al. MammoSite and interstitial brachytherapy for accelerated partial breast irradiation: factors that affect toxicity and cosmesis. *Cancer* 2004; 101: 727-734.
72. Evans SB, Kaufman SA, Price LL et al. Persistent seroma after intraoperative placement of MammoSite for accelerated partial breast irradiation: incidence, pathologic anatomy, and contributing actors. *Int J Radiat Oncol Biol Phys* 2006; 65: 333-339.
73. Niehoff P, Polgar C, Ostertag H et al. Clinical experience with the MammoSite radiation therapy system for brachytherapy of breast cancer: results from an international phase II trial. *Radiother Oncol* 2006; 79: 316-320.
74. Niehoff P, Ballardini B, Polgar C et al. Early European experience with the MammoSite radiation therapy system for partial breast brachytherapy following breast conservation operation in low risk breast cancer. *Breast* 2006; 15: 319-325.
75. Benitez PR, Keisch ME, Vicini F et al. Five-year results: the initial clinical trial of MammoSite balloon brachytherapy for partial breast irradiation in early stage breast cancer. *Am J Surg* 2007; 194: 456-462.
76. Dragun AE, Harper JL, Jenrette JM et al. Predictors of cosmetic outcome following MammoSite breast brachytherapy: a single-institution experience of 100 patients with two years of follow-up. *Int J Radiat Oncol Biol Phys* 2007; 68: 354-358.
77. Jeruss JS, Vicini FA, Beitsch PD et al. Initial outcomes for patients treated on the American Society of Breast Surgeons MammoSite clinical trial for ductal carcinoma-in-situ of the breast. *Ann Surg Oncol* 2006; 13: 967-976.
78. Belkacémi Y, Chauvet MP, Giard S et al. Partial breast irradiation as sole therapy for low risk breast carcinoma: early toxicity, cosmesis and quality of life results of a MammoSite brachytherapy phase II study. *Radiother Oncol* 2009; 90: 23-29.
79. Voth M, Budway R, Leleher A et al. Local recurrence of breast cancer after MammoSite brachytherapy. *Am Surg* 2006; 72: 798-800.
80. Baglan KL, Martinez AA, Frazier RC et al. The use of high-dose-rate brachytherapy alone after lumpectomy in patients with early-stage breast cancer treated with breast-conserving therapy. *Int J Radiat Oncol Biol Phys* 2001; 50: 1003-1011.
81. Vicini FA, Kestin L, Chen P et al. Limited-field radiation therapy in the management of early-stage breast cancer. *J Natl Cancer Inst* 2003; 95: 205-211.
82. Benitez PR, Chen PY, Vicini FA et al. Surgical considerations in the treatment of early stage breast cancer with accelerated partial breast irradiation (APBI) in breast conserving therapy via interstitial brachytherapy. *Am J Surg* 2004; 188: 355-364.
83. King TA, Bolton JS, Kuske RR et al. Long-term results of wide-field brachytherapy as the sole method of radiation therapy after segmental mastectomy for T(is, 1, 2) breast cancer. *Am J Surg* 2000; 180: 299-304.
84. Kuske RR, Winter K, Arthur DW et al. Phase II trial of brachytherapy alone after lumpectomy for select breast cancer: toxicity analysis of RTOG 95-17. *Int J Radiat Oncol Biol Phys* 2006; 65: 45-51.
85. Perera F, Yu E, Engel J, Holliday R et al. Patterns of Breast recurrence in a pilot study of brachytherapy confined to the lumpectomy site for early breast cancer with six years' minimum follow-up. *Int J Radiat Oncol Biol Phys* 2003; 57: 1239-1246.
86. Arthur DW, Koo D, Zwicker RD et al. Partial breast brachytherapy after lumpectomy: low-dose-rate and high-dose-rate experience. *Int J Radiat Oncol Biol Phys* 2003; 56: 681-689.
87. Wazer DE, Lowther D, Boyle T et al. Clinically evident fat necrosis in women treated with high-dose-rate brachytherapy alone for early-stage breast cancer. *Int J Radiat Oncol Biol Phys* 2001; 50: 107-111.
88. Wazer DE, Berle L, Graham R et al. Preliminary results of a phase I/II study of HDR brachytherapy alone for T1/T2 breast cancer. *Int J Radiat Oncol Biol Phys* 2002; 53: 889-897.
89. Lawenda BD, Taghian AG, Kachnic LA et al. Dose-volume analysis of radiotherapy for T1N0 invasive breast cancer treated by local excision and partial breast irradiation by low-dose-rate interstitial implant. *Int J Radiat Oncol Biol Phys* 2003; 56: 671-680.
90. Kaufman SA, DiPetrillo TA, Price LL et al. Long-term outcome and toxicity in a phase I/II trial using high-dose-rate multicatheter interstitial brachytherapy for T1/T2 breast cancer. *Brachytherapy* 2007; 6: 286-292.
91. Krishnan L, Jewell WR, Tawfik OW et al. Breast conservation therapy with tumor bed irradiation alone in a selected group of patients with stage I breast cancer. *Breast J* 2001; 7: 91-96.
92. Fentiman IS, Poole C, Tong D et al. Inadequacy of iridium implant as sole radiation treatment for operable breast cancer. *Eur J Cancer* 1996; 32: 608-611.
93. Fentiman IS, Poole C, Tong D et al. Iridium implant treatment without external radiotherapy for operable breast cancer: a pilot study. *Eur J Cancer* 1991; 27: 447-450.
94. Fentiman IS, Deshmane V, Tong D et al. Caesium137 implant as sole radiation therapy for operable breast cancer: a phase II trial. *Radiother Oncol* 2004; 71: 281-285.
95. Polgar C, Sulyok Z, Fodor J et al. Sole brachytherapy of the tumor bed after conservative surgery for T1 breast cancer: five-year results of a phase I-II study and initial findings of a randomized phase III trial. *J Surg Oncol* 2002; 80: 121-128.
96. Polgar C, Major T, Fodor J et al. High-dose-rate brachytherapy alone versus whole breast radiotherapy with or without tumor bed boost after breast-conserving surgery: seven-year results of a comparative study. *Int J Radiat Oncol Biol Phys* 2004; 60: 1173-1181.
97. Lovey K, Fodor J, Major T et al. Fat necrosis after partial-breast irradiation with brachytherapy or electron irradiation versus standard whole-breast radiotherapy-4-year results of a randomized trial. *Int J Radiat Oncol Biol Phys* 2007; 69: 724-731.
98. Ott OJ, Lotter M, Sauer R et al. Accelerated partial-breast irradiation with interstitial implants: the clinical relevance of the calculation of skin doses. *Strahlenther Onkol* 2007; 183: 426-431.
99. Ott OJ, Pötter R, Hammer J et al. Accelerated partial breast irradiation with iridium-192 multicatheter PDR/HDR brachytherapy: preliminary results of the German-Austrian multicenter trial. *Strahlenther Onkol* 2004; 180: 642-649.
100. Ott OJ, Schulz-Wendtland R, Uter W et al. Fat necrosis after conserving surgery and interstitial brachytherapy and/or external-beam irradiation in women with breast cancer. *Strahlenther Onkol* 2005; 181: 638-644.
101. Harris JR, Levine M, Svensson G et al. Analysis of the cosmetic results following primary radiation therapy for stages I and II carcinoma of the breast. *Int J Radiat Oncol Biol Phys* 1979; 5: 257-261.
102. Cox JD, Stetz J, Pajak TF. Toxicity criteria of the Radiation Therapy Oncology Group (RTOG) and the European Organization for Research and Treatment of Cancer (EORTC). *Int J Radiat Oncol Biol Phys* 1995; 31: 1341-1346.
103. LENT SOMA tables. *Radiother Oncol* 1995; 35: 17-60.