

Selection of surgical technique in treatment of pressure sores

Edward Lewandowicz¹, Henryk Witmanowski^{1,2}, Daria Sobieszek¹

¹Clinic of Plastic, Reconstructive and Aesthetic Surgery, Medical University of Lodz, Poland

Head: Prof. Julia Kruk-Jeromin MD, PhD

²Department of Physiology, Medical University of Poznan, Poland

Head: Prof. Teresa Torlińska MD, PhD

Post Dermatol Alergol 2011; XXVIII, 1: 23–29

Abstract

Introduction: Despite advances in medicine, pressure sores are still a serious problem. The incidence of bedsores in hospitalized patients is 3% to 10%, and 20% in those with neoplasms. A group of patients at high risk of developing pressure ulcers (39%) is those with para- and tetraplegia after spinal cord injuries. The main factors responsible for developing bedsores are pressure, shearing forces and friction. Bedsores usually occur in the sacral, ischial and trochanteric regions.

Aim: To present operative methods of treating bedsores in selected patients, based on site of pressure sore and general condition, treated in the Clinic of Plastic, Reconstructive and Aesthetic Surgery, Medical University of Lodz.

Material and methods: During 2003-2009, 36 patients (25 males and 11 females) were treated for bedsores in the Clinic of Plastic, Reconstructive and Aesthetic Surgery, Medical University of Lodz. Most patients suffered from paralysis after spinal cord injuries. Trochanteric bedsores were most common (37.5%) and 7 (19%) patients had multiple bedsores. After pre-operative treatment bedsores were excised and loss of tissue was usually covered using flaps from the neighbourhood.

Results: The healing was uneventful by 30 (83%) patients. If complications occurred they were due to wound dehiscence caused by infection and poorer healing because of the general condition of the patient (for example DM). In 3 (8%) patients recurrence was observed.

Conclusions: We used mainly musculocutaneous flaps, which is thought to be the best method of treating loss of tissue after excision of bedsores.

Key words: bedsore, surgical treatment, appropriate method.

Introduction

A pressure sore is a lesion of the skin and deeper tissues, due to ischaemia because of long-lasting pressure, shearing forces and friction. Most commonly it develops above bone eminences where pressure is the greatest [1].

Pressure sores are a serious medical problem. Most frequently they occur in bedridden patients – with para- and tetraplegia, cerebral palsy, SM and those who spend most time in a wheelchair. Bedsores have been found in Egyptian mummies. Today, despite huge medical progress, they cannot be prevented. In the literature pressure sores are found in papers dating from the first half of the 18th century. In 1938 Davis proposed surgical treatment by using flaps.

In hospitalized patients bedsores are observed in 3-10%; in cancerous patients up to 20%. Patients at high risk are those with paralysis (39%) [2]. The size of bedsores is proportional to their duration [3]. Most palsy is related to spinal cord injuries. According to the literature over 60% of spinal cord injuries occur in the lower cervical spinal cord (C5-Th1); they are caused by falls from height (60%) and crashes (30%) [4]. Since the 19th century it has been known that the main aggravating factor is persistent pressure, leading to circulatory dysfunction, ischaemia, hypoxia and tissue necrosis.

It was thought that pressure over 35 mmHg causes the changes. Now all pressure no matter the value or duration is significant in the development of pressure ulcers. Other external factors such as friction, shearing forces

Address for correspondence: Edward Lewandowicz MD, PhD, Clinic of Plastic, Reconstructive and Aesthetic Surgery, Medical University of Lodz, S. Kopcińskiego 22, 90-153 Łódź, Poland, tel. +48 42 677 67 41, e-mail: chir.gastroenterol@wp.pl

and patient's skin condition (for example lesions from urine and faeces) also play a role. Internal factors contributing to higher risk of developing pressure sores are diseases aggravating healing, for example diabetes mellitus, blood vessel diseases, malnutrition, general weakness, and urinary and faecal incontinence. Examinations by Kaneko *et al.* demonstrated that patients with pressure sores have lower levels of albumins, lymphocytes, zinc and blood platelets [5]. Marjolin's ulcer may develop on pressure ulcers. It is squamous cell carcinoma, commonly with a bad clinical course, and a tendency to local recurrence and metastases [6].

The NORTON point scale is used to define the probability of developing pressure ulcers (Tab. 1).

Decubitus ulcers most frequently occur on: ischial (about 30%), trochanteric (about 20%), lumbosacral (about 17%) and heel (9%) regions (Fig. 1-4). Sometimes they are also observed in the kneecap, elbow and popliteal fossa region (Fig. 5).

The aim of this paper is to present methods of operating on bedsores in patients treated in the Clinic of Plastic, Reconstructive and Aesthetic Surgery, Medical University of Lodz.

Material and methods

During 2003-2009 in our clinic 36 patients (25 males and 11 females) were treated for bedsores. Most patients had palsy after spinal cord injuries. Trochanteric bedsores were most common (Tab. 2). Seven patients had multiple pressure ulcers.

Surgical treatment was planned individually, depending on the size and site of the pressure ulcer as well as the general condition of the patient. At first deficits in protein and haemoglobin ratio were eliminated. The wound was prepared in a conservative fashion by frequently changing dressings and removing necrotic tissue. The patients were given an antibiotic starting on the day of the surgery and for the next 4 days; the antibiotic was chosen based on a smear from the pressure ulcers. Preventive treatment for pressure ulcers was performed perioperatively in all patients.

Surgical treatment involved excision of necrotic tissues with recesses and scars and resection of bone eminences causing pressure on soft tissues.

Loss of tissue after excision was treated with adipocutaneous, musculocutaneous or fasciocutaneous flaps well supplied with blood.

Tab. 1. NORTON point scale used to define the probability of developing bedsores. Result > 14 = higher risk of pressure sores

Risk factors	Points			
	4	3	2	1
A Physical condition	Good	Rather good	Serious	Very severe
B State of consciousness	Alert	Apathy	Disorders of consciousness	Stupor or coma
C Activity, mobility	Able to walk	Walk with assistance	Wheelchair	Bedridden
D Degree of freedom in changing position	Full	Restricted	Partial disability	Full disability
E Function of anal and urethral sphincters	Full	Sporadic incontinence	Severe incontinence	Total urinary and faecal incontinence

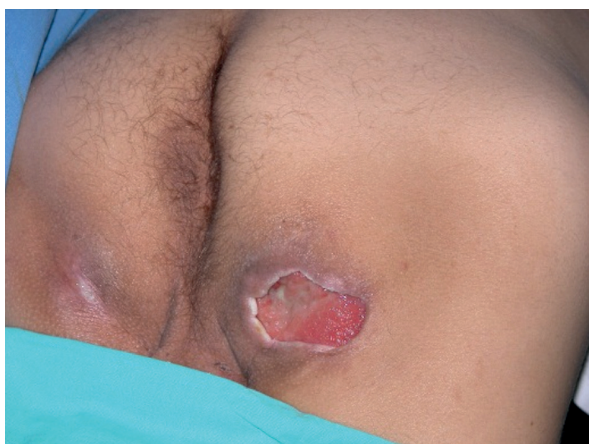

Fig. 1. Ischial pressure sore

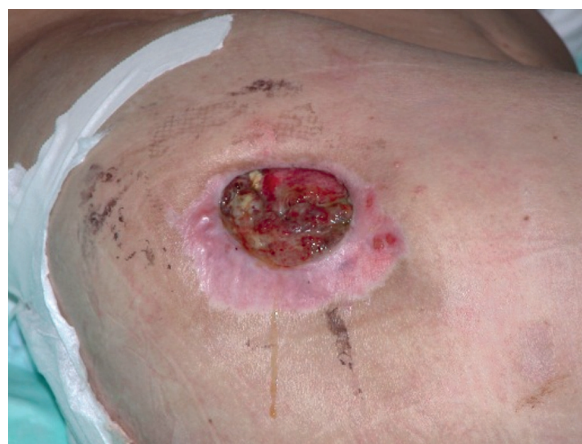

Fig. 2. Trochanteric pressure sore

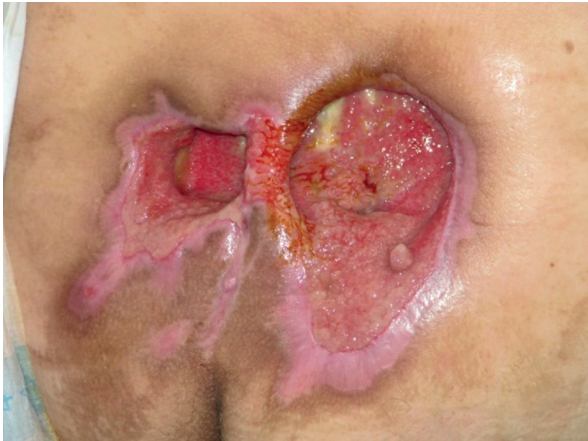

Fig. 3. Lumbosacral pressure sore

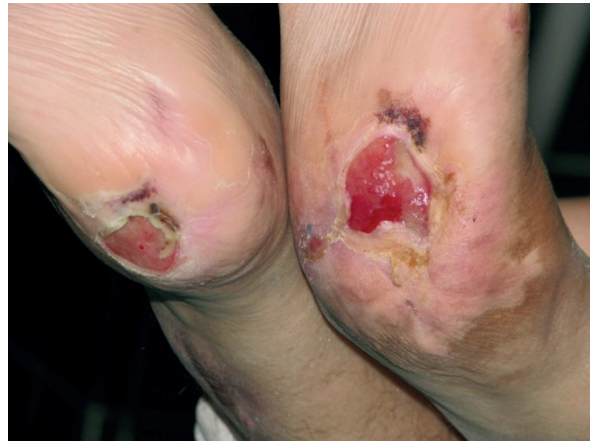

Fig. 4. Heel pressure sore

Tables 3-5 show the number of different flaps used in surgical treatment of sacral, ischial and trochanteric bedsores.

Results

Surgical techniques used in treating bed sore wounds in patients hospitalized during 2003-2009 are presented. 60 patients were operated on. All used flaps survived. Healing was uneventful by 30 (83%) out of 36 patients. In 6 (17%) patients there were complications due to partial wound dehiscence because of infection. By 3 (8%) patients bed sore recurrence was observed within 4-12 months after the surgery.

Review and discussion

Most patients suffering from bedsores in our clinic were paralysed, and despite prophylaxis and surgical treatment, relapses occurred. Therefore, when planning flap plasty a possibility of collecting another flap with good perfusion must be taken into consideration. The flap cov-

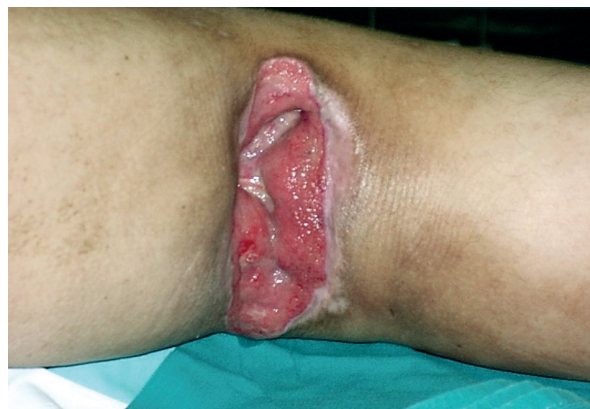

Fig. 5. Pressure sore in popliteal fossa region

ering the loss of tissue should be appropriately wide, long and well supplied with blood. In patients with no permanent paralysis (palsy), flap collection should not cause dysfunctions.

The loss of the soft tissue above the sacral bone was filled with a musculocutaneous flap, taken from the great

Tab. 2. Site of bedsores in patients treated in the clinic during 2003-2009

Site of pressure ulcer	N (%)	
Left trochanteric	13 (20%)	24 (37.5%)
Right trochanteric	11 (17%)	
Left ischium	10 (15.5%)	19 (30%)
Right ischium	9 (14%)	
Lumbosacral	17 (26.5%)	
Popliteal fossa	2 (3%)	
Heel	2 (3%)	
Total	64 (100%)	

Tab. 3. Flaps used to cover loss of tissues after excision of sacral pressure sores

Used flap	N (%)	
Musculocutaneous flap with m. gluteus maximus, rotational	9 (53%)	13 (76%)
Musculocutaneous flap with m. gluteus maximus, double-sided	3 (18%)	
Musculocutaneous flap with m. gluteus maximus, V-Y	1 (6%)	
Adipocutaneous flap	3 (18%)	
Fasciocutaneous flap	1 (6%)	
Total	17 (100%)	

Tab. 4. Flaps used to cover loss of tissues after excision of ischial pressure sores

Method used	N (%)
Musculocutaneous flap with m. biceps femoris	8 (42%)
Musculocutaneous flap with m. gluteus maximus	3 (16%)
Rotational musculocutaneous flap with m. biceps femoris	2 (10.5%)
Fasciocutaneous femoris lateralis flap	1 (5%)
Fasciocutaneous flap + m. gluteus	1 (5%)
Musculocutaneous flap with m. tensor fasciae latae	2 (10.5%)
Only simple excision without flaps	2 (10.5%)
Total	19 (100%)

Tab. 5. Flaps used to cover loss of tissues after excision of trochanteric pressure sores

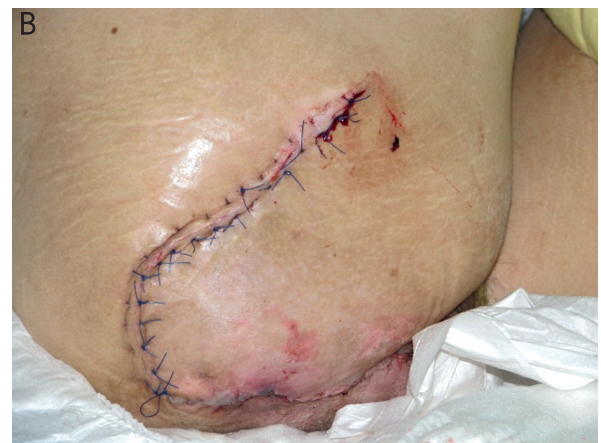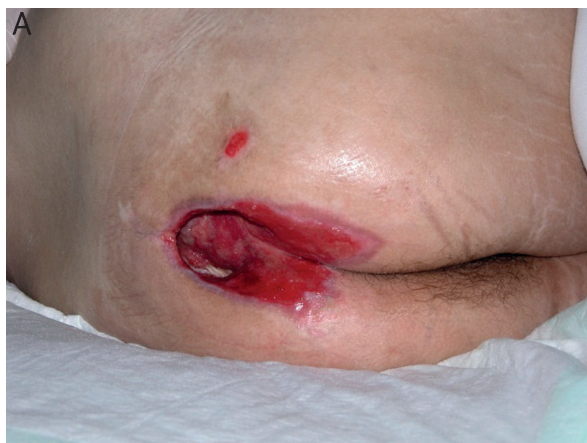Method used	N (%)
Musculocutaneous flap with m. tensor fasciae latae	8 (33%)
Musculocutaneous flap with m. biceps femoris	5 (21%)
Musculocutaneous flap with m. gluteus maximus, rotational	4 (17%)
Musculocutaneous flap with m. vastus lateralis, rotational	4 (17%)
Adipocutaneous flap from thigh	1 (4%)
Free skin graft	1 (4%)
Without flaps	1 (4%)
Total	24 (100%)

gluteal muscle, and used as a rotational flap (Fig. 6) or V-Y plasty. Perfusion of this flap is optimal because it comes from two arteries – gluteal lower and upper. The

flap innervation is provided by gluteal branches of the ischiadic nerve. Another advantage of this flap is only slight loss of the muscle's function, especially if only the upper or lower part of it is used. The site from which the flap was collected was usually sutured or covered with a free skin graft. Other authors have also successfully used it [7-9]. Wong *et al.* [9] showed that this flap is more resistant than a fasciocutaneous flap from the gluteal area. Its modifications, for example a bilateral flap with V-Y plasty [10] (Fig. 7), are also successfully used. A good alternative in extensive loss of tissues is a pedunculated fasciocutaneous flap composed of a classic musculocutaneous flap with great gluteal muscle and eccentrically pedunculated by a perforator flap [11].

Loss in the trochanter area was usually completed with a flap from the tensor fascia lata (Fig. 8). It may be used as a rotational flap. Branches of the thigh surrounding the lateral artery supply it with blood. Innervation comes from upper gluteal nerve branches. Collection is not difficult in this area and the flap is long, which enables a wide range of implementation. This method, with modifications, is used most often by other authors [12-14]. The lower part of the great gluteal muscle, lateral vastus muscle of the thigh and musculocutaneous flap of straight muscle of the thigh have also been used. Ischiadic bedsores were usually closed with a musculocutaneous flap with biceps femoris (Fig. 9, 10) nourished by a few lancinating branches of thigh profound artery from the site of collection was covered using V-Y plasty. Innervation of this flap comes from branches of the tibial posterior nerve [15, 16]. A musculocutaneous flap from straight muscle of the thigh has been used as well. Its nerve supply comes from branches of the femoral nerve. Its disadvantage is a significant loss of muscle function due to dislocation of the biceps femoris muscle. It is not significant in patients with permanent limb paralysis.

In the literature, a double rotational fascio-adipose flap is considered to be safe and appropriate in small bed-

**Fig. 6.** 24-year-old patient suffering from SM with multiple bedsores. Sacral pressure sore excision and gouge tuber of sacral bone (A); Z-plasty in upper pole of wound (B)

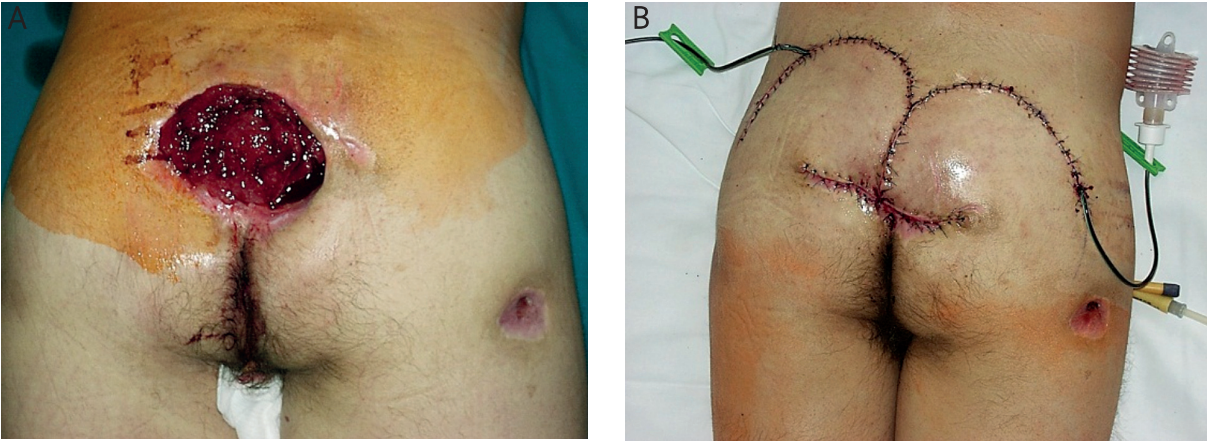


Fig. 7. 20-year-old patient – sacral pressure sore was excised (A), loss of tissue was closed by double-sided musculocutaneous flaps with m. gluteus maximus (B)

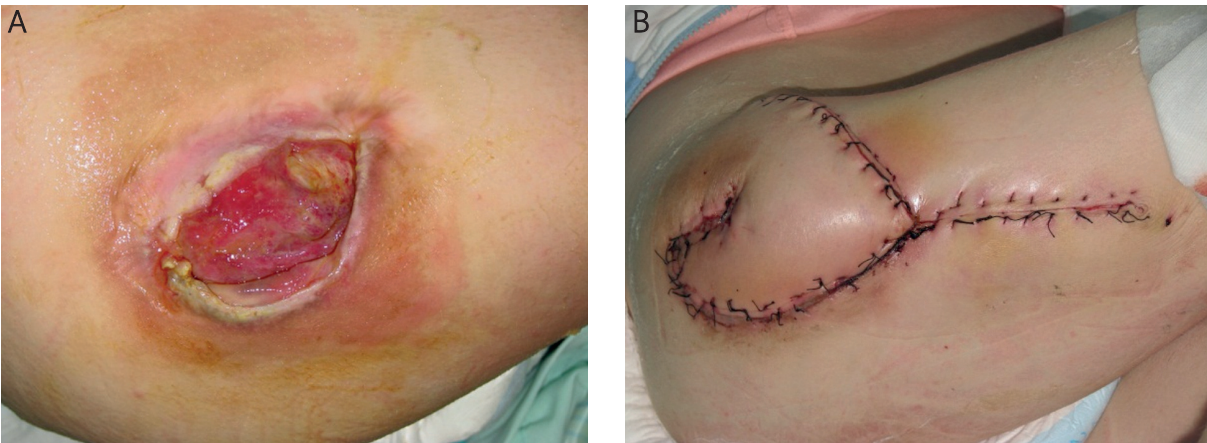


Fig. 8. 32-year-old patient after vertebral column fracture (Th 8-9) with transverse spinal cord injury. Spastic paraplegia; right trochanteric bedsore (A) was closed by musculocutaneous flap from m. tensor fasciae latae after gouge trochanter major femoris bone (B)

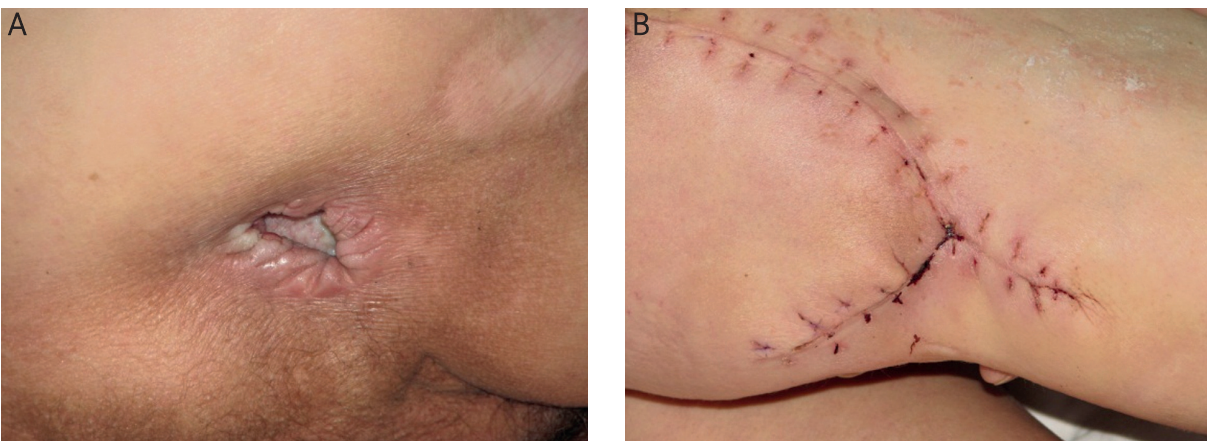


Fig. 9. 58-year-old patient after vertebral column injury with paraplegia after fall from height. Ischial (both sides) pressure sores (A). Bedsores were closed by using musculocutaneous flaps with m. tensor fasciae latae (TFL) and V-Y plasty (B)

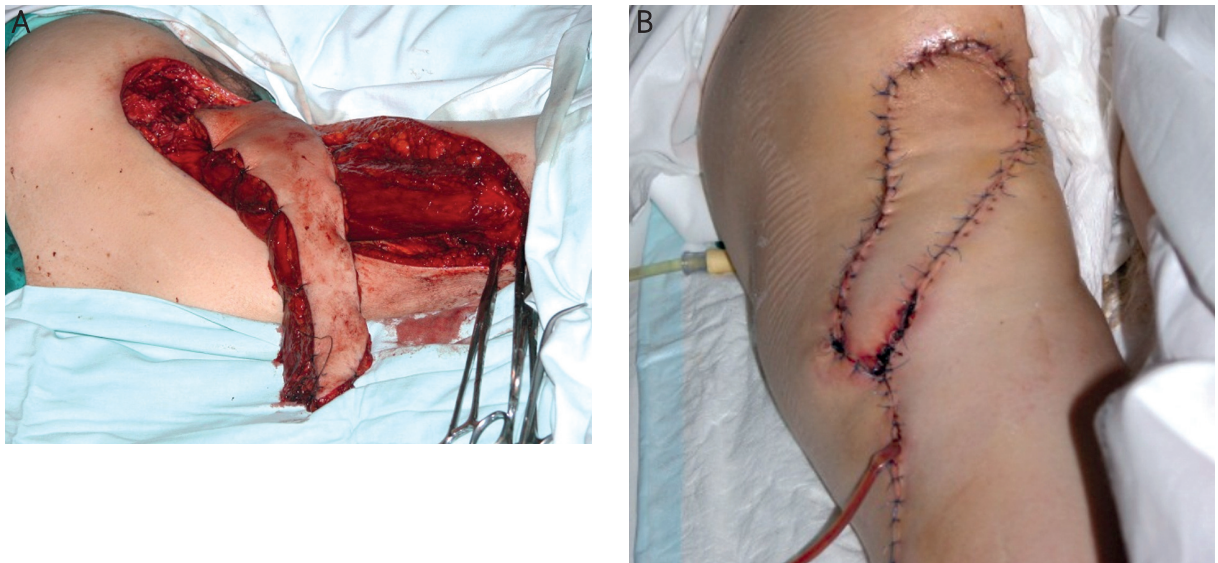


Fig. 10. 40-year-old patient with lower limb paralysis. Left ischial pressure sore, about 1.5 cm in diameter (pouch 5 cm); unsuccessful attempt to close bedsore in another hospital (A). In our clinic pressure sore was excised and loss of tissue was treated with musculocutaneous flap from biceps femoris muscle (B)

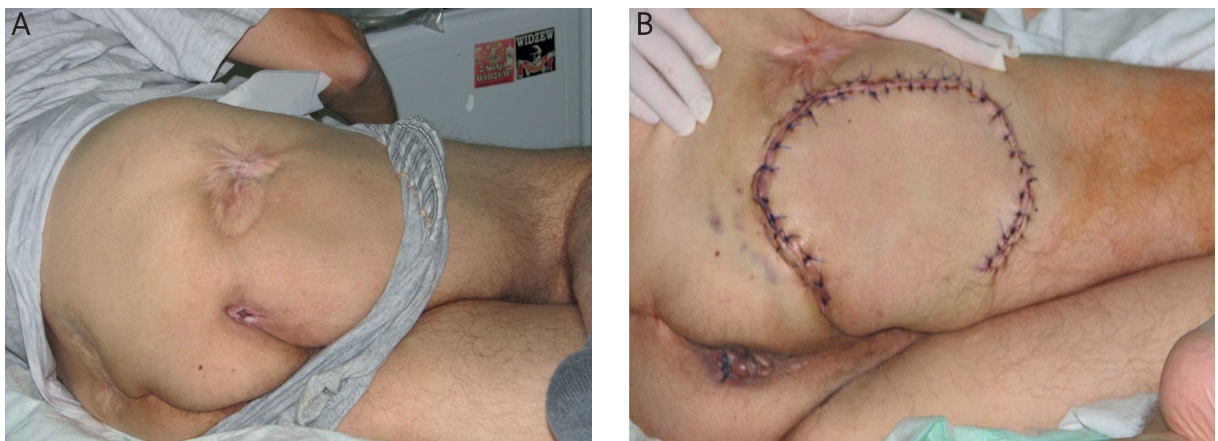


Fig. 11. 33-year-old patient after injury of cervical segment of vertebral column. Upper and lower limb palsy. Right ischial pressure sore (A). Bedsore was removed and loss of tissues was reconstructed with long head of biceps femoris muscle and fascio-muscular flap from back – lateral thigh area (B)

sores [17]. Other authors often use a fasciocutaneous femoral posterior flap or combined – the latter one with biceps of thigh in this area [18] (Fig. 11). Modifications of the classical flaps can also be used. Borgognone *et al.* suggest using a musculocutaneous "criss-cross" flap created from two flaps: muscular, from the great gluteal muscle, and a local rhomboid fasciocutaneous flap, as a safe alternative in recurrent ischiadic bedsores [19]. Kim *et al.* emphasise the numerous advantages of using an IGAP (interior gluteal artery perforator) flap in this area [20].

Postoperative complications in our patients were infection and partial wound dehiscence. They were observed in 6 patients (17%), most of whom had other

medical problems, mainly diabetes. Relapses were seen in 3 patients (8%) within 4-12 months after the surgery. They were re-operated on using a different method of closing the wound. The recurrences may have been due to insufficient prophylaxis rather than the method used, which is also confirmed by other authors [21, 22]. Our observations confirm that local plasty with a flap from the neighbourhood is the best method in treating loss of tissues in patients with pressure sores. The literature on the subject also presents the use of adipocutaneous, fasciocutaneous and musculocutaneous flaps, but it seems that the best results are observed when using musculocutaneous flaps [23, 24], which not only improve the local

blood supply in tetra- and paraplegics, but also increase tissue mass in sites at risk of pressure.

Conclusions

1. The best surgical method of treating bedsore in patients with palsy is with musculocutaneous flaps.
2. The kind and tissue content depends on the site and size of the tissue to be reconstructed and general state of the patient.
3. Fasciocutaneous flaps are most commonly used in the surgical treatment of recurrent pressure sores.
4. Preoperative treatment, both general and local, as well as bed sore prevention are vital in treating patients with pressure sores.

References

1. Bluestein D, Javaheri A. Pressure ulcers: prevention, evaluation and management. *Am Fam Physician* 2008; 78: 1186-94.
2. Wiszniewski M, Lewandowicz E. Leczenie odleżyn u pacjentów przewlekle unieruchomionych z powodu urazów i chorób rdzenia kręgowego. *Leczenie Ran* 2006; 3: 113-9.
3. Maslauskas K, Samsanavicius D, Rimdeika R, Kaikaris V. Surgical treatment of pressure ulcers: an 11-year experience at the Department of Plastic and Reconstructive Surgery of Hospital of Kaunas University of Medicine. *Medicina (Kaunas)* 2009; 45: 269-75.
4. Krasuki M, Kiperski J. Wytyczne w postępowaniu po urazach kręgosłupa w odcinku szyjnym. *Ortopedia, traumatologia, rehabilitacja* 2000; 2: 23-30.
5. Kaneko M, Maekawa M. Risk assessment of pressure ulcers occurred in perioperative and hospitalized patients. *Rinsho Byori* 2009; 57: 659-64.
6. Tan O, Atik B, Bekerecioglu M, et al. Squamous cell carcinoma in a pressure sore with a very short latency period. *Eur J Plast Surg* 2003; 26: 360-62.
7. Stamate T, Budurcă AR. The treatment of the sacral pressure sores in patients with spinal lesions. *Acta Neurochir (Suppl)* 2005; 93: 183-7.
8. Seyhan T, ErtasNM, Bahar T, Borman H. Simplified and versatile use of gluteal perforator flaps for pressure sores. *Ann Plast Surg* 2008; 60: 673-8.
9. Wong TC, Ip FK. Comparison of gluteal fasciocutaneous rotational flaps and myocutaneous flaps for the treatment of sacral sores. *Int Orthop* 2006; 30: 64-7.
10. Witkowski W, Barański M, Brom A, Olszowska-Golec M. The operative management of sacral pressure sores with a bilateral modified myocutaneous V-Y plasty. *Pol Merkur Lekarski* 2005; 18: 192-5.
11. Xu Y, Hai H, Liang Z, et al. Pedicled fasciocutaneous flap of multi – island design for large sacra defects. *Clin Orthop Relat Res* 2009; 467: 2135-41.
12. Jósavay J, Sashegyi M, Kelemen P, Donath A. Modified tensor fascia lata musculo-fasciocutaneous flap for the coverage of trochanteric pressure sores. *J Plast Reconstr Aesth Surg* 2006; 59: 137-41.
13. Karabeg R, Dujso V, Jakirlić M. Application of tensor fascia lata pedicled flap in reconstructing trochanteric pressure sore defects. *Med Arh* 2008; 62: 300-2.
14. Aslan G, Tuncali D, Bingul F, et al. The "duck" modification of the tensor fasciae lata flap. *Ann Plast Surg* 2005; 54: 637-9.
15. Jazienicki M. Operacyjne leczenie odleżynowych ubytków powłok płaciami skórno-mięśniowymi. *Pol Przegl Chir* 1996; 68: 274-83.
16. Margara A, Merlino G, Borsetti M, et al. A proposed protocol for the surgical treatment of pressure sores based on a study of 337 cases. *Eur J Plast Surg* 2003; 26: 57-61.
17. Lin H, Hou C, Xu Z, Chen A. Treatment of ischial pressure sores with double adipofascial turnover flaps. *Ann Plas Surg* 2010; 64: 59-61.
18. Ahluwalia R, Martin D, Mahoney JL. The operative treatment of pressure wounds: a 10-year experience in flap selection. *Int Wound J* 2009; 6: 355-8.
19. Borgognone A, Anniboletti T, De Vita F, et al. Ischiatic pressure sores: our experience in coupling a split-muscle flap and a fasciocutaneous flap in a 'criss-cross' way. *Spinal Cord* 2010; 48: 770-3.
20. Kim YS, Lew DH, Roh TS, et al. Interior gluteal artery perforator flap: a diable alternative for ischias pressure sores. *J Plast Reconstr Aesthet Surg* 2009; 62: 1347-54.
21. Kierney PC, Engrav LH, Isik FF, et al. Results of 268 pressure sores in 158 patients managed jointly by plastic surgery and rehabilitation medicine. *Plast Reconstr Surg* 1998; 102: 765-72.
22. Walton-Geer PS. Prevention of pressure ulcers in the surgical patient. *AORN J* 2009; 89: 538-48.
23. Zogovska E, Novevski L, Agai Lj. Our experience in treatment of pressure ulcers by using local cutaneous flaps. *Priloza* 2008; 29: 199-210.
24. Zhu XX, Hu DH, Zheng Z. Surgical treatment of multiple pressure sores. *Zhonghua Shao Shang Za Zhi* 2008; 24: 6-8.